



Hepatoprotective Effect of *Cestrum parqui* L. aerial parts and Phytochemical profile

Khaled Rashed¹, Ching-Wen Chang², Lung-Yuan Wu³, Wen-Huang Peng²

¹Pharmacognosy Department, National Research Centre, Dokki, Giza, Egypt

²Department of Chinese Pharmaceutical Sciences and Chinese Medicine Resources, College of Pharmacy, China Medical University, Taiwan

³Department of Nursing, Hsin Sheng College of Medical Care and Management, Taoyuan, R.O.C

Received: 21-05-2013 / Revised: 25-05-2013 / Accepted: 05-06-2013

ABSTRACT

This study deals with the investigation of hepatoprotective effect of 70% methanolic extract from *Cestrum parqui* aerial parts and determination of the bioactive components of the plant. The hepatoprotective effect of *Cestrum parqui* methanol extract (100, 500, 1000 mg/kg) was analysed on carbon tetrachloride (CCl₄)-induced acute liver injury. The administration of a single dose of 40% CCl₄ (1ml/kg b.w.) causes an increase in the activities of serum alanine aminotransferase (ALT) and aspartate aminotransferase (AST) enzymes and so pretreated orally of a dose from *Cestrum parqui* methanol extract (100, 500, 1000 mg/kg) and silymarin (200 mg/kg) for three consecutive days prior to The administration of a single dose of CCl₄ significantly prevented the increase in the activities of these enzymes. Histological analysis showed that *Cestrum parqui* methanol extract at doses of 500 and 1000 mg/kg and silymarin reduced the incidence of liver lesions including vacuole formation, neutrophil infiltration and necrosis of hepatocytes induced by CCl₄. The extract cause a negative result on the antioxidative enzymes, superoxide dismutase (SOD), glutathione peroxidase (GPx), glutathione reductase (GRd) and decreased malondialdehyde (MDA) level in liver, as compared to those in the CCl₄-treated group and this suggests that the hepatoprotective activity of the extract is due to the antioxidant effect of the extract. Phytochemical analysis of the methanol extract from *Cestrum parqui* aerial parts showed that it contained different phytoconstituents, flavonoids, tannins, saponins, alkaloids, terpenes and carbohydrates.

Keywords: *Cestrum parqui*, aerial parts, hepatoprotective effect, phytochemicals.



INTRODUCTION

The liver is the largest glandular organ in the body, and has more functions than any other human organ [1]. Liver diseases are very common and large public health problem in the world, however, most of medical remedies for liver diseases generally have limited efficacy and hence the use of complementary and alternative medicines (CAMs) that utilize herbal medicines have increased, and these CAMs have attracted considerable interest from patients for treating liver diseases [2, 3]. Herbal medicines have recently attracted much attention as alternative medicines useful for treating or preventing life style related disorders and relatively very little knowledge is available about their mode of action. There has been a growing interest in the analysis of plant

products which has stimulated intense research on their potential health benefits. *Cestrum parqui* from Solanaceae family, commonly known as green cestrum is a shrub native to Central and South America, it is characterized by its fetid fragrance crushing leaves [4]. *C. parqui* leaf tea was used for the treatment of smallpox, leprosy, tuberculosis, herpes, and fever. The tea may also be used as a wash for open wounds. A tea prepared from the bark is taken to induce sleep. Juice pressed from the plant may be applied to ant and other insect bites, and the leaves may be applied directly to wounds [5].

Previous phytochemical studies has shown that *C. parqui* contains solasonine and solasonidine, as well as an alkaloid known as parquine which produces effects similar to those of atropine and

*Corresponding Author Address:

Dr. Khaled Nabih Zaki Rashed, ¹Pharmacognosy Department, National Research Centre, Dokki, Giza, Egypt, E-mail: khalednabih2015@yahoo.co.uk

strychnine. Therefore, an extract of the plant has an atropine-like effect. [5] and it has also saponins and these are heterosidic derivatives formed by a steroid or triterpenic aglycon and a sugar chain. These compounds are well known for their toxic activities against several micro-organisms [6]. No further studies was undertaken for biological activities and phytoconstituents from *C. parqui* aerial parts, in this work, we investigated the hepatoprotective effect of *C. parqui* aerial parts, as well determined the phytochemicals present in the plant.

MATERIALS AND METHODS

Plant material: *C. parqui* aerial parts were collected from the Agricultural Research Centre, Giza, Egypt in May 2011 during flowering and identified by Dr. Mohammed El-Gebaly, Department of Botany, National Research Centre (NRC) and by Mrs. Tereez Labib Consultant of Plant Taxonomy at the Ministry of Agriculture and director of Orman botanical garden, Giza, Egypt. A voucher specimen is deposited in the herbarium of Agricultural Research Centre, Giza, Egypt.

Preparation of plant extract: *C. parqui* aerial parts (700 g) were extracted with methanol 70% several times until exhaustion by maceration. The extract was concentrated under reduced pressure to give 63 g. The extract was phytochemically screened using different chemical assays to identify the presence or absence of the phytochemical components in the plant according to (Connolly *et al.* 1970 [7] for sterols and/or triterpenes; Wolf *et al.* 1962 [8] for carbohydrates and saponins; Harbone 1973 [9] for flavonoids and alkaloids; Farnsworth 1966 [10] for coumarins; Geissman 1962 [11] for tannins.

Experimental animals: Mice (18-22 g) were obtained from the Bio LASCO Taiwan Co., Ltd. They were housed in standard cages at a constant temperature of 22 ± 1 °C, relative humidity $55 \pm 5\%$ with 12 h light–dark cycle (08:00 to 20:00) for 1 week at least before the experiment. Animals used in this study were housed and cared in accordance with the NIH Guide for the Care and Use of Laboratory Animals. The experimental protocol was approved by the Committee on Animal Research, China Medical University, under the code 2006-14-N. All tests were conducted under the guidelines of the International Association for the Study of Pain [12].

Study Design of CCl₄-Induced Hepatotoxicity: Mice group of the control and CCl₄ treated were orally administered distilled water. Therapeutic

control group mice were orally administered silymarin (200 mg/kg) for three consecutive days. Testing extract group mice were orally administered testing extract (100 mg/kg, 500 mg/kg and 1,000 mg/kg) for three days. One hour after the last administration of the experimental drugs, CCl₄ (1ml/kgBW, 40%) was injected intraperitoneally into mice except the mice in the normal group. The control mice received a comparable volume of olive oil (i.p.). Twenty-four hours after the CCl₄ injection, mice were sacrificed under anesthesia and blood was collected for evaluation of the biochemical parameters (AST, ALT). Liver tissue was removed for histological analysis, MDA assay, and antioxidant enzymes activity measurements.

Histological Analysis: All animals were subjected to necropsy at the end of the experiment. The liver was observed grossly and excised, blotted and weighed. The weights of the livers were also measured and presented as the percentage to the body weight. Tissues were fixed in 10% buffered formaldehyde solution and embedded in paraffin. The paraffin wax were cut into 2 μ m sections, stained with hematoxylin and eosin, and then examined under the light microscopy.

Antioxidant Enzymes Activity Measurements: SOD enzyme activity was determined according to the method of Mitchell and Brodie [13] at room temperature. One hundred micro liters of tissue extract was added to 880 μ l carbonate buffer (0.05M, pH 10.2, 0.1mM EDTA).

Twenty micro liters of 30mMepinephrine (in 0.05% acetic acid) was added to the mixture and measured at 480nm for 4 min on a Hitachi U 2000 spectrophotometer. The enzyme activity was presented as the amount of enzyme that inhibits the oxidation of epinephrine by 50% which is equal to 1 unit. GPx enzyme activity was determined according to the method of [14] at 37°C. Areaction mixture was composed of 500 μ l phosphate buffer, 100 μ l 0.01M GR (reduced form), 100 μ l 1.5Mm NADPH and 100 μ lGR (0.24 units). One hundred micro liters of the tissue extract was added to the reaction mixture and incubated at 37 °C for 10 min. Then 50 μ l of 12mM*t*-butyl hydroperoxidewas added to 450 μ l tissue reaction mixture and measured at 340nm for 180 sec. The molar extinction coefficient of $6.22 \times 10^{-3} \text{ M}^{-1} \text{ cm}^{-1}$ was used to determine the enzyme activity. One unit of activity is equal to them M of NADPH oxidized/min per mg protein. GR enzyme activity was determined following the method of [15] at 37 °C. Fifty micro liters of NADPH (2mM) in 10mM Tris buffer (pH 7.0) added in a cuvette containing 50 μ l of GSSG (20mM) in phosphate buffer. One

hundred micro liters of tissue extract was added to the NADPH-GSSG buffered solution and measured at 340 nm for 3 min. The molar extinction coefficient of $6.22 \times 10^{-3} \text{M}^{-1} \text{cm}^{-1}$ was used to determine GR enzyme activity. One unit of activity is equal to the mM of NADPH oxidized/min per mg protein.

MDA Assay: MDA was evaluated by the thiobarbituric acid reacting substance (TRARS) method [16]. Briefly, MDA reacted with thiobarbituric acid in the acidic high temperature and formed a red-complex TBARS. The absorbance of TBARS was determined at 532 nm.

Statistical Analysis: All the data was shown as mean \pm SE. Statistical analysis was carried out using one-way ANOVA followed by Scheffe's post hoc test. Histological analysis was carried out using non-parametric Kruskal-Wallis test followed by Mann-Whitney U-test. The criterion for statistical significance was $p < 0.05$.

RESULTS AND DISCUSSION

The results of hepatoprotective effect of *C. parqui* are shown in Table 1 and Figures from 1-7 and phytochemical analysis of the extract is shown in Table 2.

Plant extracts are of the most attractive sources of new drugs and have been shown to produce promising results in different pharmacological activities. Carbon tetra chloride (CCl_4) has been widely used in animal models to investigate liver injury, and is commonly employed for assessing the hepatoprotective activity of drugs [17, 18, 19]. Notably, CCl_4 is metabolized by the microsomal cytochrome P450-dependent mono-oxygenase system to produce hepatotoxic metabolites, the trichloromethyl radical ($\text{CCl}_3\cdot$) and reactive oxygen species (ROS) [19].

These radicals can react with sulfhydryl groups, such as reduced glutathione (GSH) and protein thiols, as well as initiate lipid peroxidation and protein oxidation, which cause hepatocellular membrane damage [20, 21]. Additionally, CCl_4 -induced toxicity may stimulate endogenous reactive oxygen and nitrogen species that may play important roles in the pathogenesis of hepatotoxicity [22]. Since plasma membrane permeability is associated with cell death, increased AST and ALT activities contribute to hepatic structural damage [22]. Previous studies demonstrated that CCl_4 increases serum AST and ALT levels [23, 21]. In our study, after CCl_4 treatment, the serum AST and ALT activities were increased and these

increases were attenuated by the treatment of *C. parqui* methanol extract at doses of (100, 500, 1000 mg/kg) (Fig 1, 2). The results suggest that *C. parqui* methanol extract and silymarin maintained hepatocellular membrane structural integrity and acted against CCl_4 -induced hepatotoxicity. Additionally, as compared to the control group mice, hepatic cell injury was accompanied by vacuole formation, neutrophil infiltration and extended necrotic areas of liver around portal triads in CCl_4 -treated group (Table 1, Fig.7), this phenomenon was significantly attenuated by treatment with *C. parqui* extract (500 and 1000 mg/kg) and silymarin. Lipid peroxidation plays a critical role in CCl_4 -induced liver injury [24].

To evaluate the effect of *C. parqui* extract pretreatment on CCl_4 -induced liver lipid peroxidation, MDA, the end product of lipid peroxidation was mentioned. The elevated hepatic MDA levels in the CCl_4 group are consistent with this hypothesis (Fig. 3). Therefore, maintaining near-normal levels of hepatic MDA provides additional evidence indicating that *C. parqui* extract (500 and 1000 mg/kg) and silymarin possess hepatoprotective activity. Living tissue possess a major defense mechanism involving anti-oxidative enzymes that convert active oxygen molecules into non-toxic compounds [25]. Anti-oxidative enzymes, such as SOD, GSH-Px, GSH-Rd, are easily inactivated by lipid peroxides or reactive oxygen species during CCl_4 exposure [22]. As an extremely effective antioxidative enzyme, SOD catalyzes highly reactive and potentially toxic superoxide radicals into hydrogen peroxide (H_2O_2) [26]. Glutathione (GSH) is a known radical scavenger, and GSH-related enzymes, such as GPx, GR, play detoxifying and anti-oxidative roles through conjugation with glutathione or free radical reduction [21]. This study demonstrated that the activities of SOD, GPx, and GR were decreased significantly during CCl_4 damage when compared to those of the control group (Figs. 4, 5, 6). The anti-oxidative enzymes activities in *C. parqui* extract (100, 500 and 1000 mg/kg) group were unaffected compared to those in the group treated with CCl_4 and for silymarin. It showed an increase compared to those in the group treated with CCl_4 . *C. parqui* extract has a different bioactive components, flavonoids, tannins, terpenes, alkaloids, saponins and carbohydrates (Table 2), flavonoids and saponins which is present in considerable amounts in the extract showed a good antioxidant effect [27], this may explain that the significant hepatoprotective activity of *C. parqui* aerial parts methanol extract is may be due to the antioxidant effect of the bio-active constituents in the methanol extract.

CONCLUSION

In this paper, we extracted *C. parqui* aerial parts with 70% methanol by maceration and the methanol extract showed a significant hepatoprotective effect on carbon tetrachloride (CCl₄)-induced acute liver injury, and so the methanol extract from *C. parqui* can be a good source as hepatoprotective agent and this activity may be explained by the presence of bio-active constituents, flavonoids and saponins which have a good antioxidant activity.

ACKNOWLEDGMENTS

This study is supported in part by the National Science Council, Taiwan (NSC101-2320-B-039-032-MY2), Taiwan Department of Health Clinical Trial and Research Center of Excellence (DOH100-TD-B-111-004) and Committee on Chinese Medicine and Pharmacy, Department of Health, Executive Yuan (CCMP102-RD-002).

Conflict of interest: There is no conflict of interest associated with the authors of this paper.

Table 1. Quantitative summary of the protective effects of silymarin and *Cestrum parqui* on CCl₄-induced hepatic damage based on histological observations.

Group ^b	Injury of score ^a		
	Vacuole formation	Neutrophil infiltration	Hepatocellular necrosis
Control	0	0	0
CCl ₄ (0.2% CCl ₄ /Olive oil)	1.5 ± 0.3	1.3 ± 0.3	3.5 ± 0.3
Silymarin: 200mg/kg + CCl ₄	0.9 ± 0.2 [#]	1.1 ± 0.1 ^{###}	2.8 ± 0.3 ^{###}
Extract: 0.1 g/kg + CCl ₄	2.1 ± 0.1	1.4 ± 0.1	3.6 ± 0.2
Extract: 0.5 g/kg + CCl ₄	1.2 ± 0.2	1.3 ± 0.2	2.1 ± 0.2 ^{***}
Extract: 1.0 g/kg + CCl ₄	1.6 ± 0.3	1.0 ± 0.2	2.8 ± 0.5 ^{**}

a. To quantify the histological index of vacuolization and hepatocellular necrosis of liver; they were graded 0-4 according to the method of Knodell et al. The liver damage was graded 0-4 as following: 0 = no visible cell damage; 1 = slight (1-25%); 2 = moderate (26-50%); 3 = moderate/severe (51-75%); 4 = severe/high (76-100%). b. Values represented mean ± S.E.M. (n = 10).

[#] Indicates significant difference from the Control group ([#]p < 0.05).

* Indicates significant difference with respect to the CCl₄ group (*p < 0.05).

Table 2: Phytoconstituents of *Cestrum parqui* aerial parts Methanol extract

Constituents	Methanol extract
Triterpenes and /or Sterols	+
Carbohydrates and/or glycosides	+
Flavonoids	+
Coumarins	-
Alkaloids and/or nitrogenous compounds	+
Tannins	+
Saponins	+

+ presence of constituents, - absence of constituents

AST

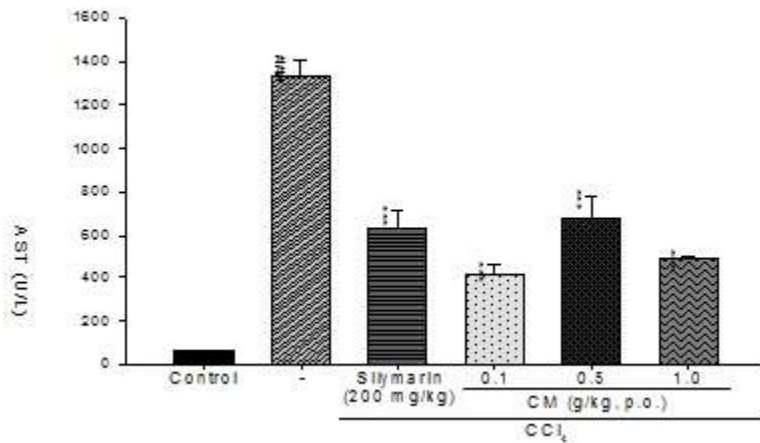


Figure 1: Effect of *Cestrum parqui* and silymarin on serum AST activity in mice treated with CCl₄. Each value was represented as mean ± S.E.M. (n = 10). ^{###}p < 0.001 as compared with the control group. ^{***}p < 0.001 as compared with the CCl₄ group (one-way ANOVA followed by Scheffe's multiple range test).

ALT

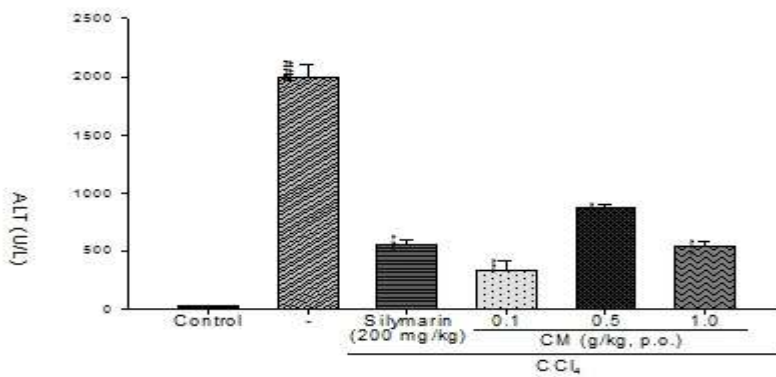


Figure 2: Effect of *Cestrum parqui* and silymarin on serum ALT activity in mice treated with CCl₄. Each value was represented as mean ± S.E.M. (n = 10). ^{###}p < 0.001 as compared with the control group. ^{***}p < 0.001 as compared with the CCl₄ group (one-way ANOVA followed by Scheffe's multiple range test).

MDA

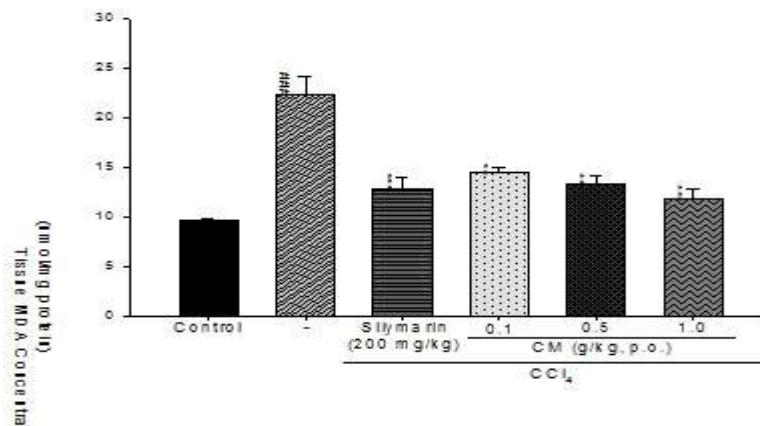


Figure 3: Effect of *Cestrum parqui* and silymarin on hepatic MDA content in mice treated with CCl₄. Each value represents as mean ± S.E.M. (n = 10). ^{###}p < 0.001 as compared with the control group. ^{**}p < 0.01 and ^{***}p < 0.001 as compared with the CCl₄ group (one-way ANOVA followed by Scheffe's multiple range test).

SOD

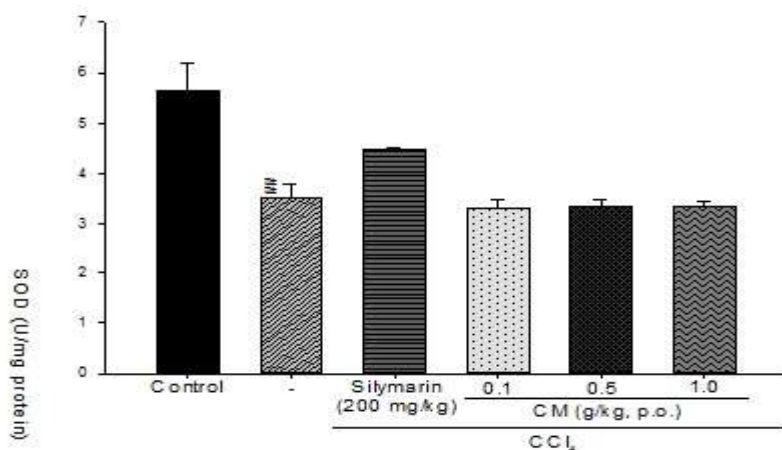


Figure 4: Effect of *Cestrum parqui* and silymarin on hepatic SOD content in mice treated with CCl₄. Each value represents as mean ± S.E.M. (n = 10). [#]p<0.01 as compared with the control group. (one-way ANOVA followed by Scheffe's multiple range test).

GSH-Px

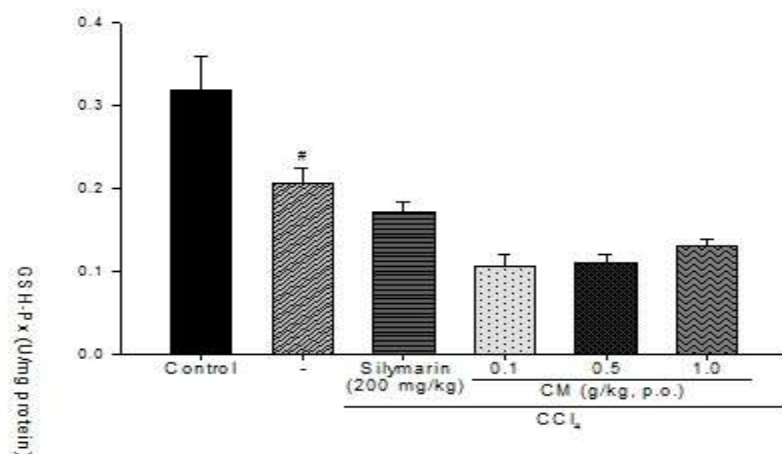


Figure 5: Effect of *Cestrum parqui* and silymarin on hepatic GSH-Px content in mice treated with CCl₄. Each value represents as mean ± S.E.M. (n = 10). [#]p<0.05 as compared with the control group. (one-way ANOVA followed by Scheffe's multiple range test).

GSH-Rd

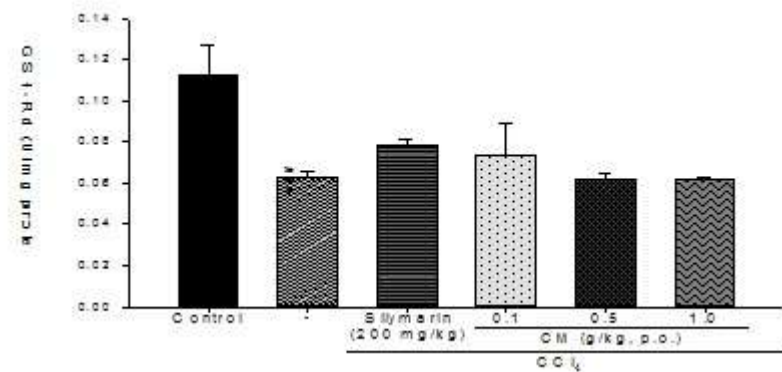


Figure 6: Effect of *Cestrum parqui* and silymarin on hepatic GSH-Rd content in mice treated with CCl₄. Each value represents as mean ± S.E.M. (n = 10). ^{###}p<0.001 as compared with the control group. (one-way ANOVA followed by Scheffe's multiple range test).

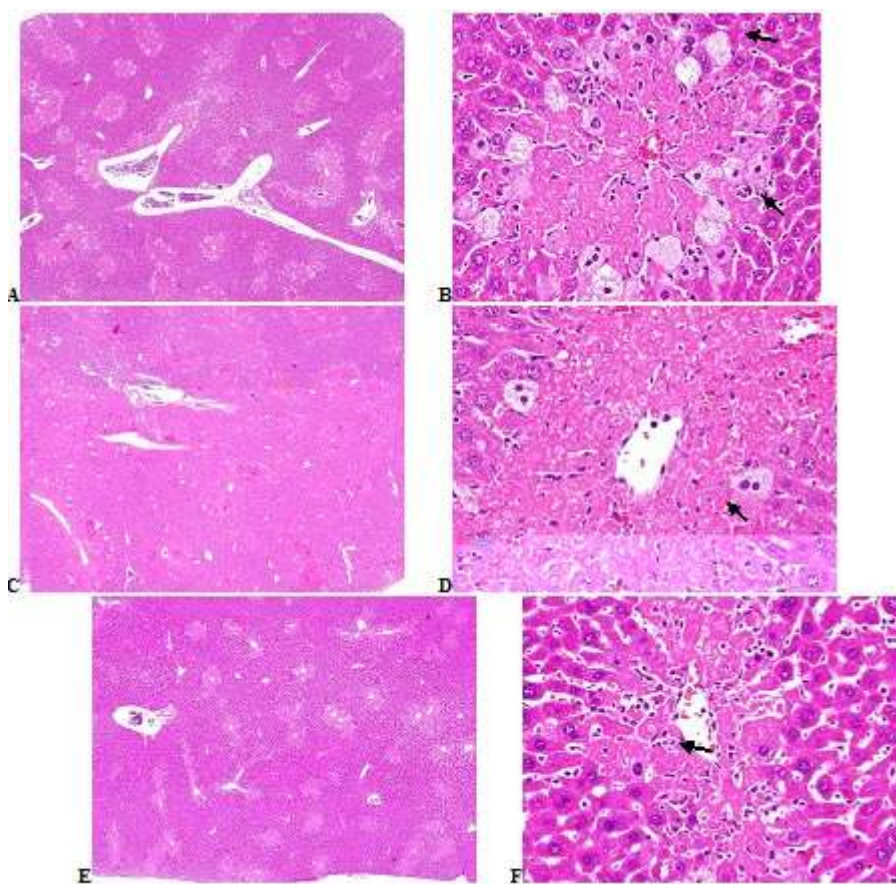


Figure 7: Histopathological alterations of CCl₄-induced acute hepatic injury in R-treated mice. CCl₄-treated mice were cotreated with R produced hepatocellular vacuolization, and hepatic necrosis in the portal area was graded as moderate (3) in *Cestrum parqui* L (A and B), moderate severe (4) in *Cestrum parqui* M (C and D), and *Cestrum parqui* H (E and F), 40x and 400x. H&E stain.

REFERENCES

1. Zakim D et al. Zakim and Boyer 's Hepatology: A textbook of Liver Disease. Saunders Elsevier, Philadelphia, PA, 2006, pp. 1-16.
2. Seeff, LB, Lindsay KL, Bacon BR, Kresina TF, Hoofnagle JH. Complementary and alternative medicine in chronic liver disease. *Hepatology* 2001; 34:595-603,
3. Strader DB et al. Use of complementary and alternative medicine in patoents with liver disease. *Am. J. Gastronterol* 2002; 97: 2391-2397.
4. Ragonese AE, Milano VA. Vegetales y sustancias toxicas de la flora Argentina. *Enciclopedia argentina de agricultura y jardineria. T2, Fasc.8-2*, Edit. Acme S.A.C.I. Buenos Aires, Argentina, 1984.
5. Ratsch C. *The Encyclopedia of Psychoactive Plants: Ethnopharmacology and its Applications*. Rochester: Park Street Press, 1998.
6. Oleszek WA, Bialy Z. Chromatographic determination of plant saponins-An update. *J Chromatogr A* 2006; 112:78-91.
7. Connolly JD et al. The chemistry and biochemistry of the linonoids and quassinoids. In: Reinhold I, Liwashitz Y (eds) *Progress in phytochemistry*. Wiley, London, 1970, pp. 385-396.
8. Wolf HH et al. Anticonvulsant properties of some N-substituted hydanoins. *J Phrama Sci* 1962; 51: 74-76.
9. Harbone JB. *Phytochemical methods*. Chapman & Hall, London, 1973.
10. Farnsworth NR Biological and phytochemical screening of plants. *J Phrama Sci* 1966; 55: 225-276.
11. Geissman TA. *The Chemistry of flavonoids compounds*. Pergamon, London, 1962, pp.126-138.

12. Zimmermann M. Ethical guidelines for investigations of experimental pain in conscious animals. Pain 1983; 16:109-110.
13. Mitchell JR et al. Acetaminophen-induced hepatic necrosis. IV. Protective role glutathione. J Pharmacol Exp Ther 1973;187:211-217.
14. Flohe L, Gunzler WA. Assays of glutathione peroxidase. Methods Enzymol 1984; 105:114-121
15. Carlberg I., Mannervik B. Glutathione reductase. Methods Enzymol 1985;113: 484-490,
16. Draper H.H. and Hadley M. Malondialdehyde determination as index of lipid peroxidation. Methods Enzymol 1990; 186:421-431,
17. Manibusan MK, Odin M Eastmond DA. Postulated carbon tetra chloride mode of action: A review. J. Environ. Sci. Health C. Environ. Carcinog Ecotoxicol Rev 2007; 25: 185-209.
18. Rao PS et al. Tissue injury and repair as parallel and opposing responses to CCl₄ hepatotoxicity: A novel dose-response. Toxicol 1997; 118: 181-193.
19. Waber LW et al. Hepatotoxicity and mechanism of action of haloalkanes: carbon tetra chloride as a toxicological model. Crit Rev Toxicol 2003; 33: 105-136.
20. Lee CH et al. Protective mechanism of glycyrrhizin on acute liver injury induced by carbon tetra chloride in mice. Biol Pharm Bull 2007a; 30:1898-1904.
21. Lee CP et al. Hepatoprotection of tea seed oil (*Camellia oleifera* Abel.) against CCl₄-induced oxidative damage in rats. Food Chem Toxicol 2007b; 45: 888-895.
22. Recknagel RO et al. Mechanisms of carbon tetra chloride toxicity. Pharmacol. Ther 1989; 43:139-154.
23. Lee TY et al. Protective mechanism of *Salvia miltiorrhiza* on carbon tetra chloride-induced acute hepatotoxicity in rats. J Pharmacol Sci 2003; 91: 202-210.
24. Basu S. Carbon tetrachloride-induced lipid peroxidation: eicosanoid formation and their regulation by antioxidant nutrients. Toxicol 2003; 189(1-2):113-27.
25. Margail I et al. Antioxidant strategies in the treatment of stroke. Free Radic Biol Med 2005; 39, 429-443.
26. Reiter RJ et al. Actions of melatonin in the reduction of oxidative stress. A review. J Biomed Sci 2000; 7: 444-458.
27. Hopia L, Heinonen H. Antioxidant activity of flavonol aglycones and their glycosides in methyl linoleate. J Amer Oil Chemistry s' Soc 1999; 76 (1): 139-144.