



Methimazole affected spermatogenesis and enhanced proliferation of testicular macrophages in albino rats

Yosry A. Okdah

Department of Zoology, Faculty of Science, Menoufia University, Shebin El-kom, Egypt

Received: 30-04-2013 / Revised: 25-05-2013 / Accepted: 20-06-2013

Abstract

The present work studied the effect of the antithyroid drug, methemazole (MMI) in testis of rat. Moreover, the effect of MMI on testicular macrophages was studied. The MMI-treated rats received diet food and 0.1% methimazole drinking water for 30 days. The results showed that MMI caused reduction in body weight of the animals. Histological examination of the testis revealed significant decrease in diameter of seminiferous tubules and inhibition of spermatogenesis. A significant increase in the number of macrophages was recorded in the testicular interstitium. The highest number of macrophages was found in close proximity to Leydig cells followed by peritubular location. The lowest number was observed in perivascular location. Macrophages are necessary to remove cellular remnant like apoptotic material or cell debris in inflammable tissue. So the increase in macrophage number recorded in this work suggests that either apoptotic or inflammable processes rise in rat testicular interstitium after exposure to methimazole.

Keywords: Methimazole, Testis, Rats, Macrophages



INTRODUCTION

Hypothyroidism studies in humans and experimental animals showed that it is associated with delayed puberty and abnormal gonadal function. Many studies have examined the effects of hypothyroidism during pre- and post-natal development or in prepubertal and pubertal male rodents [1-3]. Methimazole (MMZ) (1-methyl-2-mercaptoimidazole) and Propylthiouracil (PTU) (6-propyl-2-thiouracil) are frequently used as antithyroid drugs. It acts by inhibitory action on thyroid peroxidase mediated iodination of tyrosine residues in thyroglobulin. This is very important step in thyroxine and triiodothyronine synthesis [4]. Methimazole, an antithyroid drug induces hypothyroidism in rat [5]. The effect of methimazole on male fertility was studied. It was observed that gestational exposure to methimazole decreased sperm forward motility, *in vivo* fertilizing ability, bioavailability of androgens, AR status, and secretory activity of the epididymis in adult rats [6]. The authors concluded that transient gestational-onset hypothyroidism affects male fertility by impairing post testicular sperm maturation process in the epididymis, owing to

subnormal androgen(s) bioavailability. Daily administration of 0.05% methimazole to the nursing mothers induced many changes in newborn male rats; significantly reduced seminiferous tubules diameter, the proliferation and differentiation of germ cells were arrested and their number were decreased [2]. Also, the absolute weight of testes, plasma testosterone, estradiol and sex hormone binding globulin levels were significantly decreased. Macrophages are necessary to remove cellular remnant like apoptotic material or cell debris in inflammable tissue [7]. The present work studied the role of macrophages in testis of rats treated with methimazole.

MATERIAL AND METHODS

Animals and treatment: The rats (*Rattus norvegicus*) were treated at the Dept. of Zoology, Faculty of Science, Menoufia University, Shebin Elkom (Egypt). The experiments were permitted by the authorities of Menoufia University; Rules of Animal Protection of the Faculty of Science, Menoufia University were obeyed. 3-months old male albino rats were used for this study. The animals were allocated to 2 groups (1 treated with

**Corresponding Author Address:*

Yosry A. Okdah, Department of Zoology, Faculty of Science, Menoufia University, Shebin El-kom, Egypt,

E-mail: Yosryokdah59@yahoo.com

antithyroid drug methimazole = MMI, 1 sham-fed with normal diet food and drinking water: each group consists of 5 animals). The MMI-treated rats received diet food and 0.1% methimazole drinking water for 30 days (3 g methimazole was dissolved in 3 l water and was consumed by 5 rats, so that 600ml 0.1% methimazole drinking water was taken by one rat in 30 days). 24 h after the last dosage the animals were decapitated under light ether anesthesia, the testes were removed quickly and fixed in Bouin's solution. 5 μ m thick serial paraffin sections were cut from each testis.

Histology and immune histochemistry: Three sections from each testis were stained with PAS-haemalaun to examine the histology, the state of spermatogenesis and the diameter of the testicular tubules. To identify the testicular macrophages immune histochemically the primary antibody ED 1 (mouse anti-rat CD 68, Serotec, Niederaula, Germany; dilution: 1: 500) was employed. Tris buffered saline with pH 7.4 was used as a buffer solution. Three sections from each testis were used for immune histochemistry. The sections were deparaffinized, treated 5 min. with a proteolytic enzyme (Dako, Denmark), and incubated with 3% H₂O₂ for 20 min. at room temperature, and incubated with the primary antibody at 4°C in refrigerator for 16 h in a moist chamber. As a secondary antibody (30 mn. at room temperature) the EnVision+R system labeled polymer-HRP anti mouse (Dako, Denmark) was used. The reaction product was stained with DAB; the sections were finally covered with DepeX. For the negative control sections, the primary antibody was replaced with the buffer solution.

Cell counting and Evaluation: The ED 1 -positive testicular macrophages were counted using a cell counting grid in the ocular of the microscope with the objective x 25. The macrophages were counted in all three sections of each testis and expressed as mean per mm² of the section. All data were analyzed by student's t-test of two independent means. Differences between mean values were considered to be significant if p-value was less than 0.05.

RESULTS

Effects of methimazole on body weight and behavior: Methimazole-treated rats suffered from loss of body weight. While rats of the control group showed an increase in body weight from 150±10 g per rat at the experiments beginning to 225±10 g per rat at the end, the treated ones weighed only 125±9 g per rat at the end of the experiment. One rat died after methimazole treatment during the 4th

week. Treated rats suffered from loss of body balance, vestibular disturbances and temporarily from epileptic changes and circling in the cage.

Histological changes in spermatogenesis: In control rats all stages of spermatogenesis were found. The seminiferous epithelium was of normal appearance (Fig.1a&b). In methimazole-treated rats the most advanced cell type of spermatogenesis was lost (fig.2a &b). Few tubules showed also some spermatids in the beginning of elongation, mostly without condensation. Exfoliation of germ cells was observed in the seminiferous epithelium frequently and some tubules showed severe reduction of spermatogenesis (Fig.2a). In treated rats the tubules diameter decreased significantly from a mean value of 266 ± 10 μ m in controls to 187± 10 μ m (p<0.01) in methimazole-treated animals.

Changes in testicular macrophages: Rats which were treated with antithyroid drug methimazole for 30 days showed a significant increase in the number of macrophages in the testicular interstitium. In control rats most macrophages (Fig.3 a&b), identified by immune histochemical reaction of ED 1, were found in close proximity to Leydig cells (349/mm²) and only few macrophages were found in perivascular location (29/mm²). Rats which were treated with methimazole for 30 days showed a clear increase in the proliferation of macrophages (Fig.4 a&b). Macrophages increase was analysed quantitatively by a cell counting which yielded a statistically significant rise in the number of macrophages (p<0.001). The highest number of macrophages was found in close proximity to Leydig cells (1124/mm²) followed by peritubular location (792/mm²); the lowest number was observed in perivascular location (298/mm²) (Fig.5). However, here the highest percentage increase (nearly 10-fold) of macrophages number was found. The increase in the total number of macrophages was nearly 3.5-fold (Fig.6).

DISCUSSION

The results of the present study supply quantitative data about macrophages in normal adult rat testis and about how their number develops after treatment with methimazole (MMI). The present study tried to find out whether administration of the antithyroid drug methimazole to male rodents adversely affects spermatogenesis or influences macrophage number or not. It shows that methimazole leads to a significant increase in the number of testicular macrophages. Comparable findings occur in infertile male patients with Sertoli cell only or germ cell arrest syndromes, where the

overall macrophage number was increased over twofold [7]. In contrast to that study, where they found that the highest increase in macrophage number was in peritubular location.

The data demonstrates that after methimazole treatment the highest macrophage number could be finding in close proximity to Leydig cells. Macrophages were detected with ED 1, a monoclonal antibody which recognizes the antigen which is the rat homologue of human CD 68. It has been shown that the expression of this antigen in cells increases during phagocytic activity [8], leading to the conclusion that as a result of methimazole treatment the phagocytic activity in rat testicular interstitium increase.

Macrophages are necessary to remove cellular remnant like apoptotic material or cell debris in inflammable tissue. So an increase in macrophage number suggests that either apoptotic or inflammable processes rise in rat testicular interstitium after exposure to methimazole. Studies which have differentiated two types of macrophages, showed that ED I -positive cells correspond to circulating phagocytes and ED 2 detected resident macrophages [9]. Probably circulating macrophages are important to sustain inflammatory responses within the testis [10].

It has been demonstrated that after experimental testicular infection of rats with Sendai virus, a virus related to mumps virus, there was an increase of ED 1-positive circulating monocytes, while the number of resident macrophages did not change [9]. These findings consider that methimazole possibly causes a testicular inflammation and that circulating macrophages were recruited and reach the interstitial tissue through the blood vessels. Interestingly, in our study the lowest number of macrophages was found in perivascular location, however the highest percentage increase was found in that location, too.

Methimazole, an antithyroid drug induces hypothyroidism in rat [2, 5, 11]. Many studies have examined the effects of hypothyroidism during pre- and post-natal development or in prepubertal and pubertal male rodents [1-3]. In contrast to those studies the present work tried to find out how experimental induced hypothyroidism affects male adult rats. The obtained data demonstrate that methimazole causes an increase in macrophage number in adult rat testicular interstitium; leading to the conclusion that hypothyroidism raises phagocytic activity and monocyte migration. It has been shown that high plasma levels of thyroid hormones suppressed the migration of monocytes

and that hypothyroidism lead to an increase in phagocytic capacity, but in contrast to our results they found out that cell migration is not effected [12]. Hypothyroidism influences tubular diameters, germ cell numbers and sperm density depending on temperature and duration of treatment [13]. That can be supported by the present data, where it also found a decrease in seminiferous tubules diameter and at least a developmental delay in spermatogenesis. Other studies showed that the duration of treatment with an antithyroid drug is important for the effects on testis weight and volume as well as on Leydig cell numbers [11].

It has been suggested that thyroid hormones regulate the duration of Sertoli cell proliferation and the capacity of the testis to produce sperm [14]. Thyroid hormones are important for normal spermatogenesis [2] and congenital hypothyroidism causes a prolonged proliferation of Sertoli cells during postnatal development, developmental delay in the appearance of spermatocytes and spermatids, subsequent apoptosis of germ cells after maturation and a reduction in the height of the seminiferous epithelium [15].

These findings suggest that the methimazole induced increase in macrophage number is caused by an increase in germ cell apoptosis which can lead to infertility. It has been shown that neonatal hypothyroidism leads to a testicular hypertrophy in adulthood with an increase in Sertoli cells [16- 17]. Because Sertoli cells can only support a finite number of germ cells [18- 19] that could lead to the conclusion that more germ cells were supported by enlarged number of Sertoli cells but it has been show that hypothyroid rats were infertile [20]. Furthermore, there are studies which have shown that hypothyroidism causes reduced levels of gonadotropins in the serum and a delay in pubertal spermatogenesis caused by retarded differentiation of Sertoli cells [21]. Spermatogenesis could be adversely affected by thyroid hormone deficiency because proliferating Sertoli cells as well as germ cells express thyroid hormone receptors so that the essential role of thyroid hormones on the testicular development can be supported [22].

Neonatal hypothyroidism leads to an increase in Leydig cell number in adulthood [23- 24] and to a delay in their differentiation from precursor into adult Leydig cells [25]. These findings suggest that methimazole has an influence on testicular Leydig cells which can be a reason for the highest increase in macrophage number in close proximity to Leydig cells in our study.

CONCLUSION

This study demonstrates that methimazole adversely affects testicular macrophages by inducing an increase in macrophage number over three-fold. Furthermore, it has an effect on rat spermatogenesis and leads to reduced seminiferous

tubule diameter, as well as it reduced body weight of rats. So methimazole induced hypothyroidism spermatogenesis and can lead to infertility.

Conflict of interest statement: I declare that I have no conflict of interest

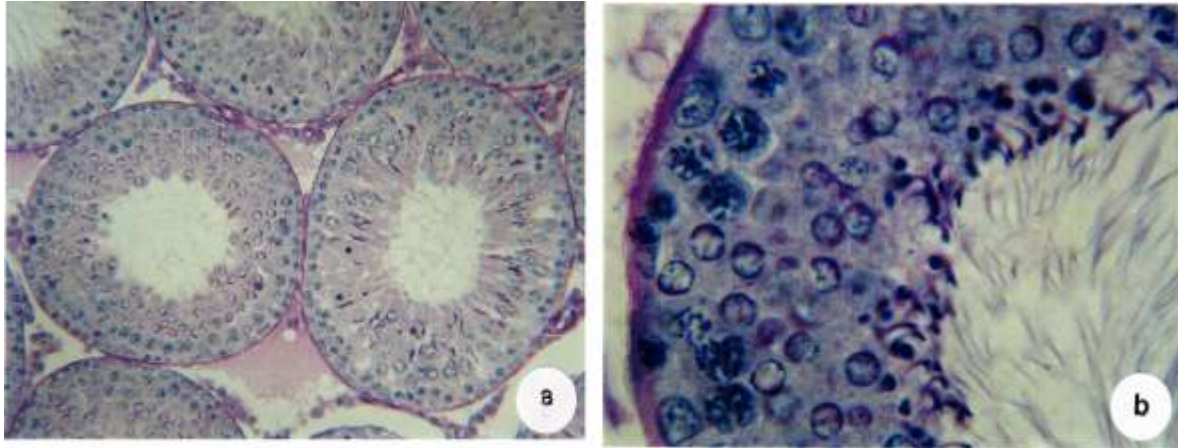


Figure 1: **a.** Section in testis of a control rat showing seminiferous tubules(X 200), and **b.** Enlarged seminiferous tubule showing all stages of spermatogenesis(X 500).

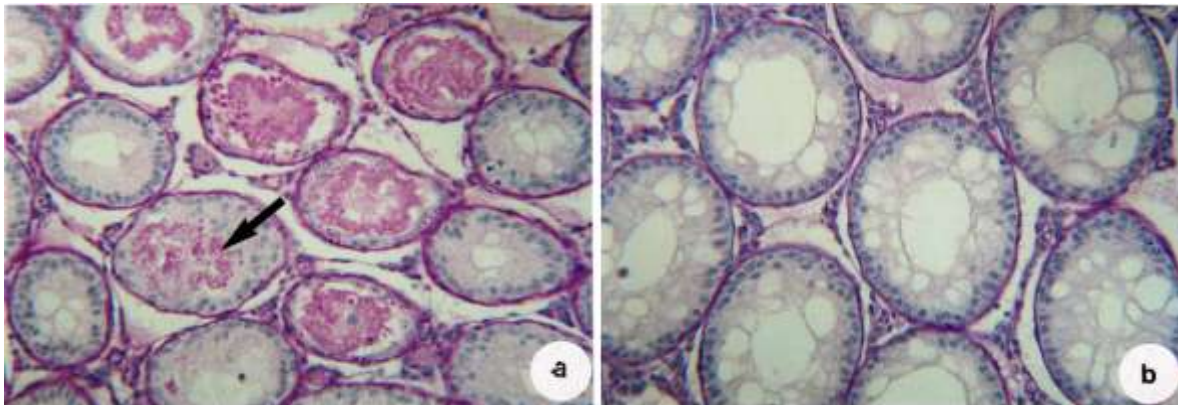


Figure 2: **a.** Section in testis of methemazole-treated rat showing exfoliation of spermatogenic cells (arrow)(X 200) and **b.** Seminiferous tubules with loss of spermatogenic cells, (X 200).

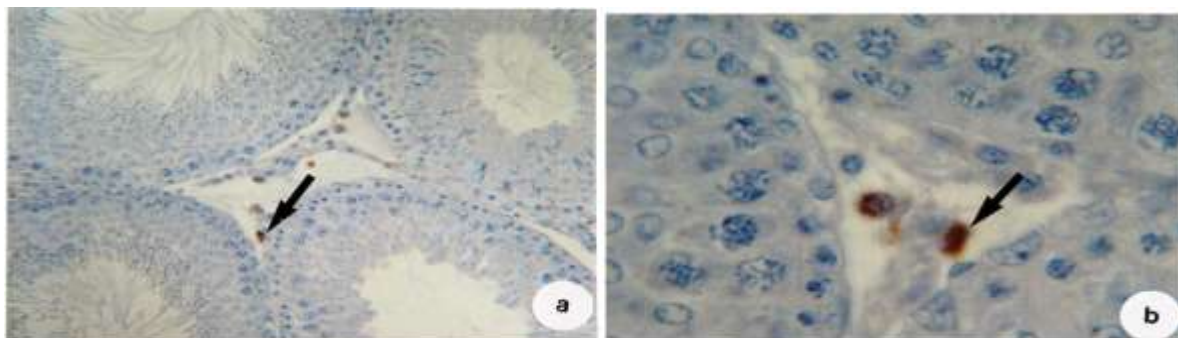


Figure 3: **a.** Immunohistochemical reaction of ED 1 (brown), nuclear staining with hematoxylin (blue) in the interstitial area of controls (arrow) (X200) and **b.** Enlarged stained Leydig cells (arrow), (X 500).

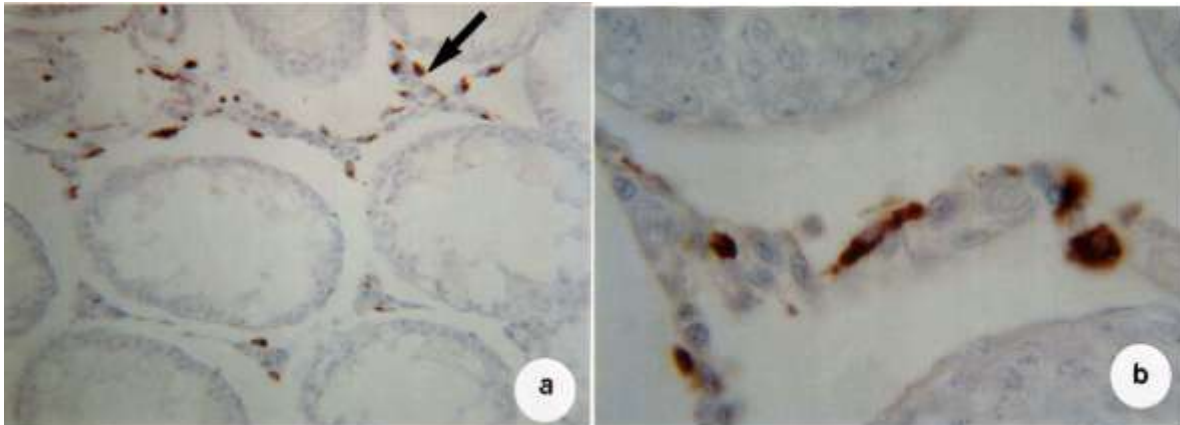


Figure 4: **a.** Immunohistochemical reaction of ED 1 (brown) in methimazole-treated rat (arrow) (X200) and **b.** Enlarged stained Leydig cells (arrow), (X 500).

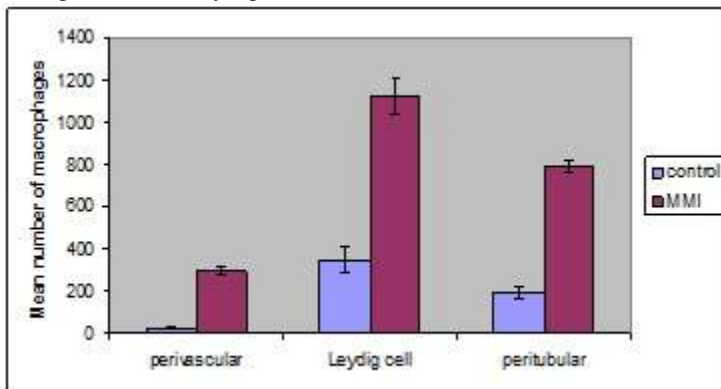


Figure 5: Mean number of macrophages in perivascular, Leydig cell vicinity and peritubular regions of testes of animals after 30 days of treatment with methimazole.

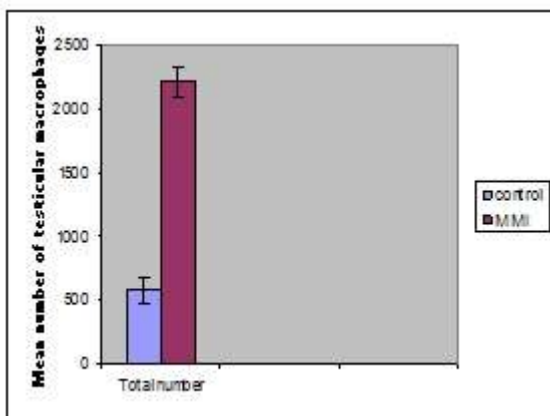


Figure 6: total mean number of macrophages in control and methimazole group.

REFERENCES

1. Wagner MS, et al. Hypothyroidism induces type 2 iodothyronine deiodinase expression in mouse heart and testis. *J Mol Endocr* 2003; 31: 541-550.
2. Maran RR, Aruidhas MM. Adverse effects of neonatal hypothyroidism on Wistar rat spermatogenesis. *Endocr Res* 2002; 28: 141-154.
3. Mendis-Handagama SMLC, et al. Differentiation of adult Leydig cells in the neonatal rat testis is arrested by hypothyroidism. *Biol Reprod* 1998; 59: 351-7.
4. Cooper SD. Antithyroid drugs. *N Engl J Med* 2005; 352: 905-17.

5. Cristovao FC, et al. Severe and mild neonatal hypothyroidism mediate opposite effects on Leydig cells of rats. *Thyroid* 2002; 12:13-8.
6. Anbalagan J, et al. Mechanism underlying transient gestational-onset hypothyroidism-induced impairment of posttesticular sperm maturation in adult rats. *Fertil Steril* 2010; 93: 2491-7.
7. Frungieri MB, et al. Number, distribution pattern, and identification of macrophages in the testes of infertile men. *Fertil Steril* 2002; 78: 298-306.
8. Bauer J, et al. Phagocytic activity of macrophages and microglial cells during the course of acute and chronic relapsing experimental autoimmune encephalomyelitis. *J Neurosci Res* 1994; 38: 365-375.
9. Melaine N, et al. Experimental inoculation of the adult rat testis with Sendai virus: effect on testicular morphology and leukocyte population. *Hum Reprod* 2003; 18: 1574-9.
10. Hedger MP. Macrophages and the immune responsiveness of the testis. *J Reprod Immunol* 2002; 57: 19-34.
11. Maran RR, et al. Transient neonatal hypothyroidism alters plasma and testicular sex steroid concentration in pubertal rats. *Endocr Res*. 2000; 26: 411-429.
12. Rosa LF, et al. Effect of hypo- and hyperthyroidism on the function and metabolism of macrophages in rats. *Cell Biochem Funct* 1995; 13: 141-7.
13. Lagu SK, et al. Neonatal hypothyroidism-induced changes in rat testis size; dependence on temperature. *Neuro Endocrinol Lett* 2005; 26
14. Buzzard JJ, et al. Thyroid hormone, retinoic acid, and testosterone suppress proliferation and induce markers of differentiation in cultured rat Sertoli cells. *Endocrinology* 2003; 144: 3722-373 1.
15. Sakai Y, et al. Developmental delay and unstable state of the testes in the rdw rat with congenital hypothyroidism. *Dev Growth Differ* 2004; 46: 327-334.
16. Kimura T, Furudate S. Pituitary GH and prolactin deficiency and testis enlargement in hypothyroid rats caused by goitrogen methimazole. *Exp Anim* 1996; 45: 369-375.
17. Cooke PS, et al. Triiodothyronine inhibits proliferation and stimulates differentiation of cultured neonatal Sertoli cells: Possible mechanism for increased adult testis weight and sperm production induced by neonatal goitrogen treatment. *Biol Reprod* 1994; 51:1000-1005.
18. Li H, Kim KH. Effects of mono-2-ethylhexyl phthalate on fetal and neonatal rat testis organ cultures. *Biol Reprod* 2003; 69: 1964-1972.
19. Orth JM, et al. Evidence from Sertoli cell-depleted rats indicates that spermatid number in adults depends on numbers of Sertoli cells produced during perinatal development. *Endocrinology* 1988; 122: 787-794.
20. Jiang JY, et al. Characteristics of infertility and the improvement of fertility by thyroxine treatment in adult male rdw rats. *Biol Reprod* 2000; 63: 1637-1641.
21. Francavilla S, et al. Effect of thyroid hormone on the pre- and post-natal development of the rat testis. *J Endocrinol* 1991; 129: 35-42.
22. Buzzard JJ, et al. Developmental expression of thyroid hormone receptors in the rat testis. *Biol Reprod* 2000; 62: 664-9.
23. Hardy MP, et al. Increased proliferation of Leydig cells induced by neonatal hypothyroidism in the rat. *J Androl* 1996; 17: 231-8.
24. Hardy MP, et al. Leydig cells increase their numbers but decline in steroidogenic function in the adult rat after neonatal hypothyroidism. *Endocrinology* 1993;132: 2417-2420.
25. Teerds KJ, et al. Development of adult-type Leydig cell population in the rat is affected by neonatal thyroid hormone levels. *Biol Reprod* 1998; 59: 344-350.