



## **Hepatoprotective effect of ginger extract against the toxicity of 7, 12-dimethylbenz (a)anthracene (DMBA) in albino rats**

Doaa A. Ali\*, Mohamed F. Ismail and Heba A. Badr

Department of Zoology, Faculty of Science, Mansoura University, Mansoura, Egypt

**Received: 20-06-2013 / Revised: 02-07-2013 / Accepted: 13-07-2013**

### **ABSTRACT**

The present work was conducted to study the protective effect of ginger extract (GE) against the hepatotoxicity induced by 7, 12-dimethylbenz(a)anthracene (DMBA) in female rats. DMBA treated group showed a highly significant decrease in body weight. However, DMBA+GE treated group displayed a highly significant increase in body weight compared with DMBA treated group. Histologically, the liver of DMBA treated group showed nodule-like structures, hepatic cirrhosis, congestion of blood vessels, intercellular hemorrhage, hepatic pyknotic nuclei, lymphocytic infiltration, dilation of blood sinusoids and large amount of collagen fibres. DMBA+GE treated group displayed an improvement in the hepatic lesions induced by DMBA. Histochemically, the liver sections of DMBA treated group showed a marked depletion of polysaccharides and total protein content. However, DMBA+GE treated group showed a moderate increase in liver polysaccharides and total protein contents. Immunohistochemically, the hepatocytes of DMBA treated group showed a highly significant increase in the PCNA labelling index. However, DMBA+GE treated group displayed a highly significant decrease in the PCNA labelling index when compared with DMBA treated group.

**Key Words:** Ginger, DMBA, Hepatotoxicity, Histology, Histochemistry, PCNA immunohistochemistry



### **INTRODUCTION**

7, 12-Dimethylbenz (a)anthracene (DMBA) is one of the most potent carcinogenic polycyclic aromatic hydrocarbons produced during the incomplete combustion of carbon-containing compounds, and predominantly found in tobacco smoke, whisky, grilled meat and motor vehicle exhaust emissions [1]. The conversion of DMBA to its ultimate carcinogenic metabolites is mainly accomplished by the cytochrome P450 (CYP) 1 family enzymes. In particular, CYP1A isoforms are responsible for its bioactivation in the liver, the major organ of DMBA metabolism, while CYP1B enzymes are reported to exert their activity predominantly in extra-hepatic tissues, such as the mammary gland [2]. The liver plays a central role in producing proximate mutagens that could be transported to the breast for final metabolic activation to form the ultimate DNA-reactive metabolites [3]. The toxic metabolites of DMBA including diol epoxides are capable of binding to adenine residues of DNA, causing chromosomal damage [4]. DMBA induces neoplasms in the

mammary gland, liver, heart and lungs after being metabolically activated [5].

Natural products and their active ingredients, as sources for new drug discovery and treatment of diseases, have attracted attention in recent years. Herbs and spices are generally considered safe and proved to be effective against various human ailments. *Zingiber officinale* Roscoe, commonly known as ginger, is one of the commonly used spices around the world [6]. Ginger contains active phenolic compounds that have antioxidant [7], anti-cancer [8], anti-inflammatory [9] and antithrombotic properties [10].

In spite of the intensive studies carried out on the use of ginger as immuno-modulatory, antitumorigenic, anti-inflammatory, antiapoptotic, antihyperglycemic, antilipidemic and antiemetic, there are few studies on its hepatoprotective effects. Thereby, the present work was conducted to study the protective effect of ginger extract against the histological, histochemical and immune

\*Corresponding Author Address: Doaa A. Ali, Department of Zoology, Faculty of Science, Mansoura University, Mansoura, Egypt, E-Mail: [doasakr@mans.edu.eg](mailto:doasakr@mans.edu.eg)

histochemical changes induced by DMBA in the liver of female albino rats.

## MATERIALS AND METHODS

**Chemicals:** The rhizomes of *Zingiber officinale* were brought from local market at Mansoura, Egypt. They were shade dried at room temperature and were crushed to powder. 125 g of the powder were macerated in 200 ml of distilled water for 12 hr at room temperature and filtered to obtain the final aqueous extract (24mg/ml) as previously described [11].

7,12dimethylbenz[*a*]anthracene (DMBA) was purchased from Sigma (St. Louis, MO, USA) and dissolved in corn oil.

**Experimental animals:** Healthy female (Sprague Dawley) albino rats, each weighing about 55±5g, were acclimatized to the laboratory condition. All experiments were carried out in accordance with the protocols approved by the local experimental animal ethics committee. Animals were randomly divided into four groups (n=10 per group) as follows: 1) Control group, the animals were intraperitoneally injected with a single dose of 1 ml corn oil/kg body weight; 2) Ginger extract (GE)-treated group, the animals were orally administered with 1ml of GE (120 mg/kg body weight) every other day for five months; 3) DMBA treated group, the animals were intraperitoneally injected with a single dose of 40 mg DMBA/kg body weight as previously described [12]; and 4) DMBA+GE treated group, in addition to DMBA-treatment, these animals were orally administered 1ml of ginger extract (120 mg/kg body weight) every other day for five months.

Animals were monitored daily and their body weights were recorded every week. The animals were sacrificed at the end of the experiment (i.e after five months) and the liver samples were immediately dissected out and immediately fixed in alcoholic Bouin and 10% buffered neutral formalin.

**Histological preparation:** The fixed liver specimens were dehydrated in ascending series of ethyl alcohol and embedded in paraffin. Sections at 5µm thickness were stained according to the following histological stains: H&E [13] and Masson's Trichrome Method [14] for collagen fibres.

**Histochemical investigation:** Total polysaccharides were detected histochemically using Periodic Acid Schiff's (PAS) reaction [15].

Also, the total protein was detected using mercury-bromo phenol blue stain [16].

**Immunohistochemistry:** Paraffin-embedded liver sections (4µm thick) were floated onto aminopropyltriethoxysilane (APES) coated slides, and were deparaffinated with xylene, hydrated in graded series of ethanol. Immuno-histochemical staining was performed using an avidin-biotin peroxidase complex. Endogenous peroxidase was quenched with 3% H<sub>2</sub>O<sub>2</sub>: methanol (1:1) for 30 minutes at room temperature. Staining of formalin-fixed tissues requires boiling tissue sections in 10mM citrate buffer, pH 6.0 for 20 min followed by cooling at room temperature for 20 min. The primary antibodies (monoclonal anti-proliferating cell nuclear antigen (PCNA), (Zymed Laboratories, South San Francisco, CA, USA), were diluted (1:1000) and added to the slides for 60 min at room temperature. Sections were washed twice for 5 min in PBS, followed by the addition of appropriate secondary antibody (biotinylated goat anti-rabbit IgG diluted to 1:500), followed by incubation with peroxidase- conjugated streptavidin diluted to 1:3000 in phosphate-buffered saline for 15 min. the peroxidase reaction was performed using 0.02% chromogen DAB (3,3 diaminobenzidine tetrahydrochloride). Sections were then counterstained with hematoxylin, dehydrated and mounted in Canada balsam. The positive stains are brown nuclear stain

About 100 cells/slide was counted in each of five microscopic fields to determine the average of PCNA labelling index (PCNA LI). PCNA LI was expressed as number of labelled cells (positive for PCNA) as a percentage of the total number of cells counted in each specimen.

**Statistical analysis:** Data were analyzed statistically using Student's *t*-test using SPSS software (SPSS, version15.0, Chicago, IL, USA) and the data was presented as Mean ± SEM. Differences with  $P \leq 0.05$  were considered significant.

## RESULTS

**Body weight:** As shown in Table (1), body weight of DMBA treated group shows highly significant decrease ( $P < 0.001$ ) with respect to the control group. However, DMBA+GE treated group displayed a highly significant increase ( $P < 0.001$ ) in body weight with respect to DMBA treated group. Also, Figure (1) illustrated the change in the body weight gain of the different investigated groups throughout the experiment.

**Histological observations:** DMBA-treated animals showed many pathological alterations in the hepatic tissue. The normal structural organization of the hepatic lobules was impaired and the characteristic cord-like arrangement of the normal liver cells was lost as nodule-like structures appeared (Fig. 2C). Also, hepatic cirrhosis appeared in other foci (Fig. 2E). In addition, congested blood vessels, intercellular hemorrhage, pyknotic nuclei, activation of kupffer cells, lymphocytic infiltration and dilation of blood sinusoids were evident (Fig. 2D). DMBA+GE treated group displayed remarkable improvement represented by reduced hepatocytes degeneration, sinusoids dilation and leucocytic infiltration (Fig. 2F).

Liver tissue from the control and GE-treated animals revealed collagen as blue fibres in dense bundles around blood vessels and lesser amount around the blood sinusoids (Figs. 3A&B). DMBA treated group showed large amount of collagen fibres around the central veins and blood capillaries forming a morphologic criterion for the liver cirrhosis (Fig. 3C). DMBA+GE treated group showed the normal distribution of the collagen fibres in the liver tissue particularly around the central veins (Fig. 3D).

#### **Histochemical observations**

**Total polysaccharides:** The hepatic cells of the control and GE-treated animals showed that the polysaccharides were demonstrated in the cytoplasm in the form of intensively red coloured materials accumulated mainly at one pole of the cell as shown by their strong PAS positive reactions, whereas the rest of the cytoplasm remained weakly stained (glycogen flight). The nuclei of the liver cells did not exhibit any positive staining (Figs. 4A&B). DMBA injected animals displayed a marked depletion of polysaccharides from most of the liver cells, while the hepatocytes near the central veins showed a strong PAS positive reaction (Fig. 4C). Combined treatment with GE and DMBA revealed an increase in the polysaccharide content compared to DMBA-treated animals (Fig. 4D).

**Total proteins:** The protein materials in the liver cells of the control and GE-treated animals appeared in the form of small bluish irregular particles which sometimes were packed closely together forming blue irregular dense bodies. The hepatocytes were limited by intensely-stained cell membranes and their nuclei contained positively stained nucleoli together with chromatin particles (Figs. 4E&4F). Examination of liver sections of animals injected with DMBA showed reduction of

their protein content and most of the hepatocytes appeared with cytoplasmic vacuolization (Fig.4G). Combined treatment with GE and DMBA showed a moderate increase in the protein content near the central veins and in the adjacent hepatocytes in the tissue. However, some hepatocytes still have low protein content (Fig. 4H).

**Immunohistochemical observations:** Liver sections of the control and GE-treated animals immunostained for PCNA showed few weak positive stained nuclei indicating the cell divisions of few hepatocytes (Figs. 5A&B). However, liver sections of DMBA-treated animals showed strong positive stained nuclei (Figs. 5C&D). The hepatocytes of DMBA+GE treated group demonstrated the presence of positive stained nuclei but less than that of DMBA-treated animals (Figs. 5E&F). Moreover, Figure (6) represents the changes in liver PCNA labelling index. GE-treated animals showed a nonsignificant decrease in PCNA LI when compared with that of the control animals. While, DMBA treated group displayed a highly significant increase ( $p < 0.001$ ) in PCNA LI and animals treated with both DMBA and GE illustrated a highly significant increase ( $p < 0.001$ ) in PCNA LI when compared with the control group and a highly significant decrease ( $p < 0.001$ ) when compared with DMBA treated group.

#### **DISCUSSION**

7,12 dimethylbenza[*a*]anthracene (DMBA) is a potent carcinogen and one of the polycyclic aromatic hydrocarbons. They are found throughout the environment in the air, water, and soil [1]. The conversion of DMBA to its ultimate carcinogenic metabolites is mainly accomplished by the cytochrome P450 (CYP) 1 family enzymes. CYP1A isoforms are responsible for DMBA bioactivation in the liver, the major organ of DMBA metabolism [2].

In the present study, DMBA treated group showed a highly significant decrease in body weight gain compared to the control group. The obtained results are in agreement with the findings of Mathivadhani *et al.* [17]. The loss in body weight gain are in agreement with Devlin [18] who reported that the weight loss of the treated rats is largely from skeletal muscles and adipose tissue with relative sparing of visceral proteins. Otherwise, DMBA+GE treated group displayed highly significant increase in body weight when compared to DMBA treated group and this may be due to the antioxidant activity of ginger. However, ginger is ranked one of the plants with highest antioxidant values [19].

In the present study, DMBA injection resulted in hepatocellular lesions as indicated by impaired structural organization, hepatic cirrhosis, congested blood vessels, intercellular hemorrhage, hepatic pyknotic nuclei, activation of Kupffer cells, and dilation of blood sinusoids. These findings are in accordance with the results of many other investigators [20-22]. They observed that DMBA-induced liver-carcinoma in rats indicated by the development of nodules and the liver cells displayed eosinophilic, dense and pleomorphic nuclei, cytoplasmic vacuolization and necrosis. Confirmation of the present result comes from previous studies [23, 24] which reported the development of liver tumours in toads under the effect of DMBA. In the present study, leucocytic infiltration was also observed in liver of DMBA treated group. These leucocytic infiltrations were considered as a prominent response of the body tissue facing any injurious impacts [25].

In the present work, large amount of collagen fibres around the central vein and blood capillaries were noticed as a result of DMBA injection. The deposition of extracellular matrix is the hallmark of fibrosis and cirrhosis which was evidenced. Excessive deposition of collagen could occur during an imbalance in its metabolism. Toxic material activates hepatic stellate and Kupffer cells to release reactive oxygen species (ROS) that induce the production of transforming growth factor- $\beta$  (TGF- $\beta$ ) and interleukin-6 (IL-6), all of which induce the fibrogenic process. TGF- $\beta$  and IL-6 upregulate the expression of type I collagen genes [26]. In addition, ROS can inactivate enzymes containing sulphhydryl group, especially collagenases and proteases responsible for collagen degradation, which results in accumulation of collagen in liver [27]. Moreover, the appearance of fibrin and collagen in toxic conditions is a feature of hepatocellular disorders that affect the endothelium of liver sinusoids [22, 28, 29].

In the present histochemical results, the polysaccharide content was depleted in the hepatic tissues of animals injected with DMBA. Such decrease could be either attributed to the increasing stress on hepatocytes or to loss of liver cells to store glycogen as a result of DMBA toxicity [30]. Also, liver sections of animals injected with DMBA showed reduction of their protein content. El-Banhawy *et al.* [31] indicated existence of a close parallelism between nucleic acids and the level of protein synthesis, thereby; this reduction in the protein content could be attributed to the nuclear pathological changes such as pyknosis and

karyolysis, which were evidenced in the present work and in a previous study [32].

The liver sections of DMBA treated group in the present study showed very high significant increase in the positively-stained nuclei for PCNA protein. Similarly, the administration of diethyl nitrosamine (DEN) carcinogen elevated levels of PCNA expression in mice liver [33]. Moreover, the PCNA LI increased as liver disease progressed, and its level was markedly high in hepatocellular carcinoma (HCC) [34]. However, it has been observed the increased levels of PCNA in both preneoplastic and tumour cells [35].

The present results reflect the carcinogenicity or toxicity of DMBA to the liver tissue; this may be attributed to the increased production of reactive oxygen species and inhibition of anti-oxidant enzymes, or to disturbance of their production. DMBA produces a much higher concentration of free radical than do non-carcinogenic compounds [36, 37]. These free radicals may result in cross linking of DNA, protein and lipids to each other or oxidatively damaging functional group on these important macromolecules causing molecular damage and cell injury [38, 39]. In addition, the toxic metabolites of DMBA including diol epoxides in liver tissue are capable of binding to adenine residues of DNA, causing chromosomal damage [4].

It has been reported that dietary intake of natural anti-oxidants could be an important aspect of the body defence mechanism against carcinogens [40]. Herbs and spices are generally considered safe and are proved to be effective against various human ailments and their medicinal uses have been gradually increased in developed countries. Ginger has been used extensively in folklore medicine to treat common ailments. Also, new scientific evidence emerges many beneficial properties and supports its use to ameliorate different disorders [6-10].

The present histological and histochemical observations of the liver tissue of GE treated group showed the normal construction of the liver as that of the control group indicating that GE administration did not cause any side effect or hepatotoxicity as previously described [41-43]. Moreover, the liver of both control and GE-treated rats immunostained for PCNA protein showed few positively-stained nuclei expressing normal cells in the proliferating stage. This result was in agreement with Theunissen *et al.* [44] who found nuclear immunoreactivity of PCNA in the

proliferating compartments of the normal adult tissue.

The present histological and histochemical results revealed that GE administration causes improvement in the liver toxicities induced by DMBA and goes parallel to the findings of a previous study [19]. The present observations reinforce the view that ginger scavenges free radicals produced by DMBA through its potent anti-oxidant property. It has been reported that ginger (*Zingiber officinale*) scavenges free radical, inhibits lipid peroxidation, and exhibits strong anti-oxidant properties [45, 46]. Also, chemical constituents like gingerol, shagoals, curcumin and zingerone present in ginger exhibited a strong antioxidative property [47-49]. In addition, it has been revealed that [6]-gingerol inhibits nitric oxide synthesis in activated macrophages *in vitro* and prevents oxidation and nitration reactions induced by peroxynitrite which is a strong reactive nitrogen species [50, 51].

The anti-oxidant effect of ginger inhibits the expression and signal pathways of TGF-β and the synthesis of connective tissue proteins as in the

present histological detection of collagen fibres [52, 53].

Liver sections of DMBA+GE treated group showed high significant decrease in PCNA LI with respect to DMBA treated group. This result is parallel to that obtained by previous workers [54, 55] who found that ginger constituents have inhibition activity on proliferation of cancer cells. Moreover, it has been reported that reducing cellular proliferation was one of the hallmarks of controlling the carcinogenic process [56].

**CONCLUSION**

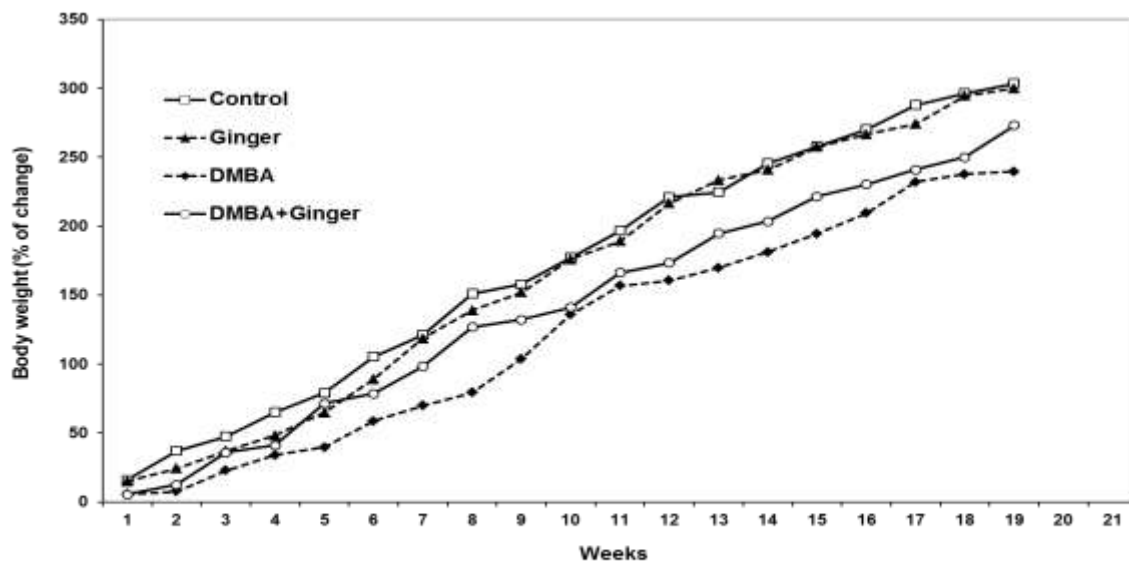
Ginger extract exhibited a hepatoprotective effect against the toxic and preneoplastic liver lesions induced by DMBA through its antioxidant chemical constituents and/or scavenging the free oxygen and nitrogen radicals produced by DMBA metabolism in the liver. Thus, the present work can provide new insights into the pharmacological targets of ginger extract in the protection of hepatotoxicity.

**Conflict of interest statement:** We declare that we have no conflict of interest.

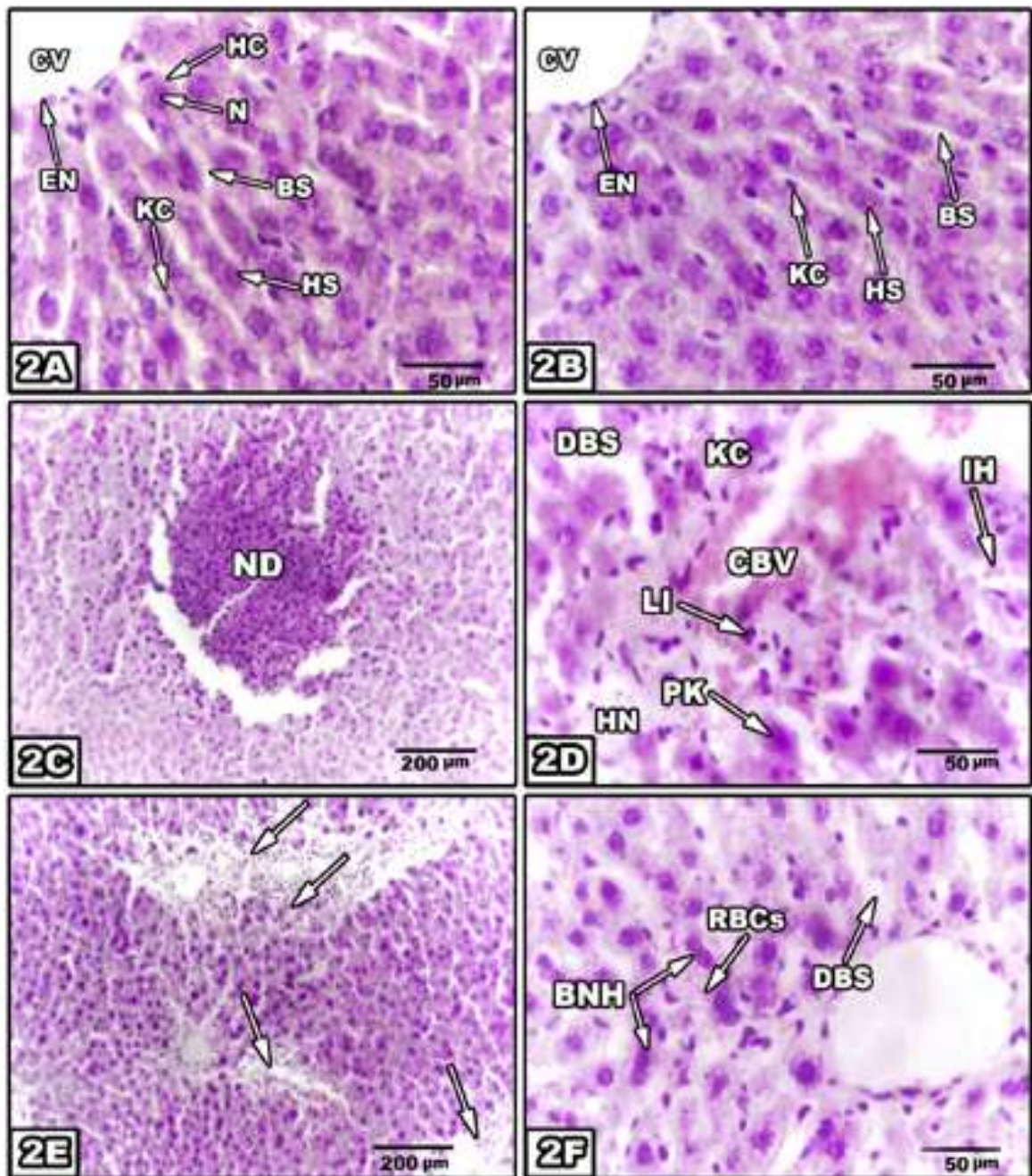
**Table 1:** Effects of the treatment with DMBA and/or GE on the body weight

| Group              | Control  | GE      | DMBA     | DMBA+GE |
|--------------------|----------|---------|----------|---------|
| Initial weight (g) | 57±2.8   | 54±1.9  | 56±3.1   | 53±2.4  |
| Final weight (g)   | 230±5.24 | 216±5.1 | 180±5.7* | 209±6** |

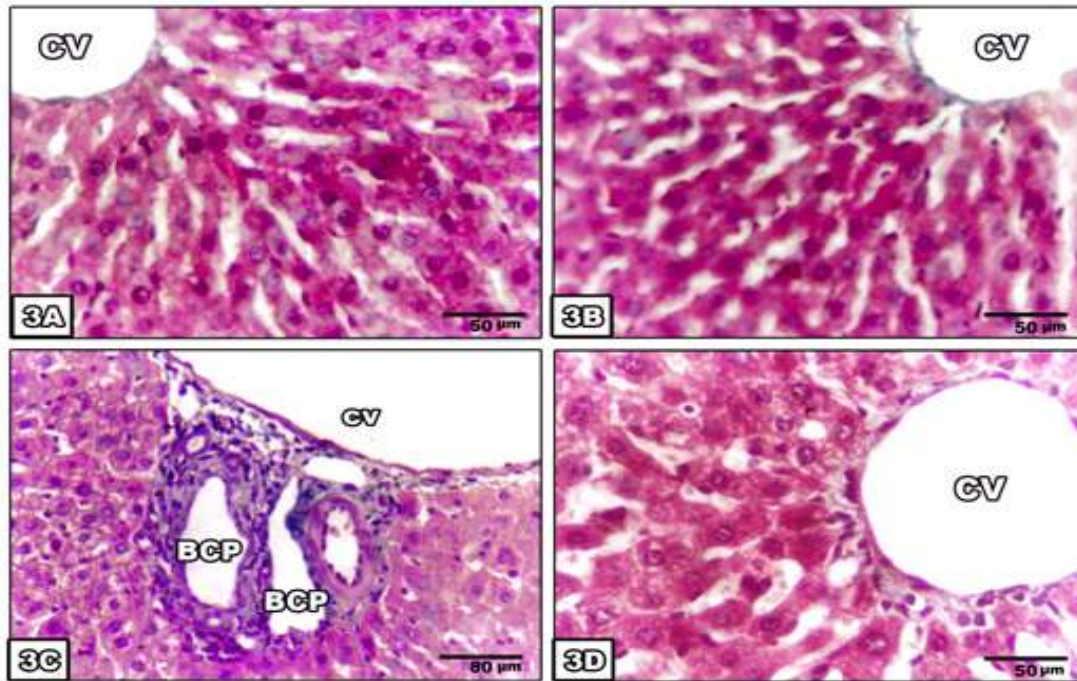
Values are expressed as mean ± SE, \* P<0.001 compared to the control group and \*\* P<0.001 compared to the DMBA treated group.



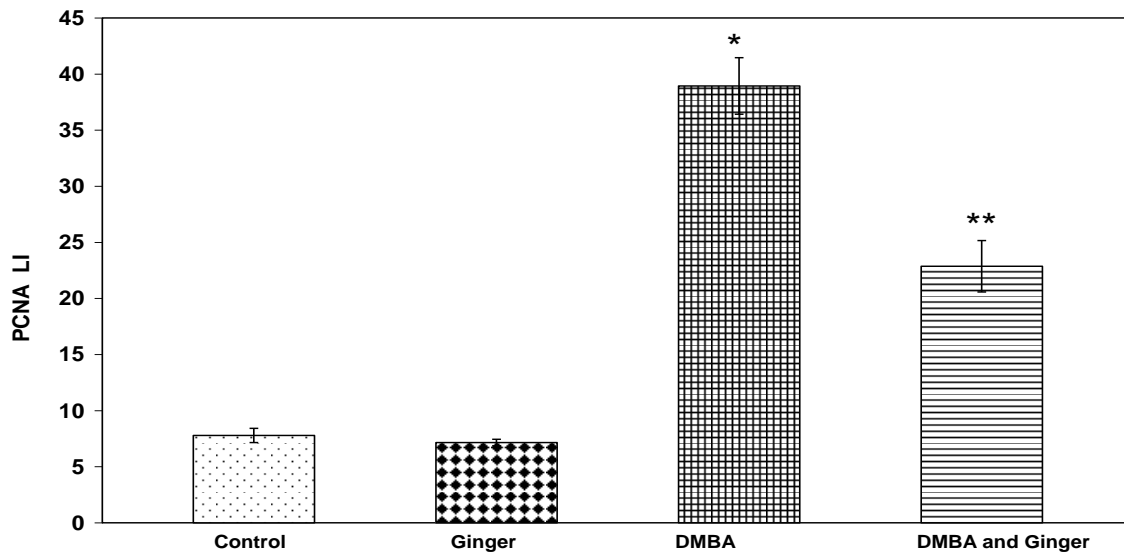
**Figure 1.** Percentage of change in the body weight gain as a result of DMBA toxicity and/or Ginger treatment.



**Figure 2:** Liver histopathology of rats treated with GE and/or DMBA. Liver section of normal control rat (2A), liver section of GE treated rat (2B) showing no remarkable changes, liver sections of DMBA injected rats (2C-2E) illustrating nodule (ND) like structure, hepatic cirrhosis (arrow), congested blood vessels (CBV), intercellular hemorrhage (IH), hepatic necrosis (HN), Pyknotic nucleus (PN), activation of Kupffer cells (KC), lymphocytic infiltration (LI) and dilation of blood sinusoids (DBS), liver section of DMBA +GE treated group (2F) displaying a few binucleated hepatocytes (BNH), dilation of blood sinusoids (DBS) and few RBCs (H & E).



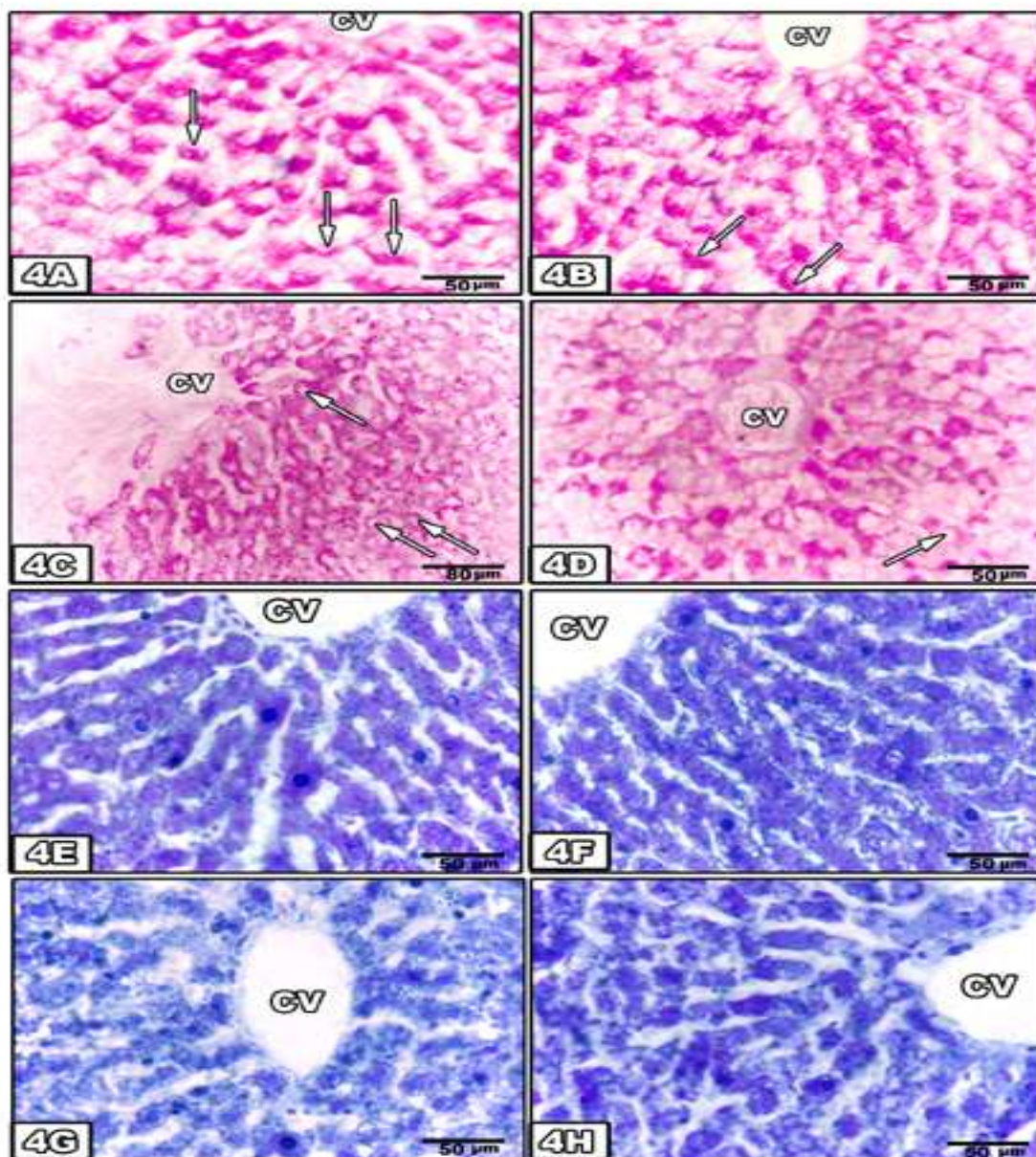
**Figure 3:** Liver histology of rats treated with GE and/or DMBA demonstrating the collagen fibres. Liver section of control rat (3A) illustrating negligible amount of collagen fibres around the central vein (CV), liver section of GE-treated rat (3B) showing no remarkable changes, liver sections of DMBA injected rats (3C) illustrating large amount of collagen fibres around central vein (CV) and around blood capillaries (BC), liver section of DMBA+GE treated group (3D) showing moderate amount of collagen fibres around the central vein (CV) (Masson trichrome stain).



**Figure 6:** Liver PCNA labelling index as a result of DMBA and/or ginger treatment.

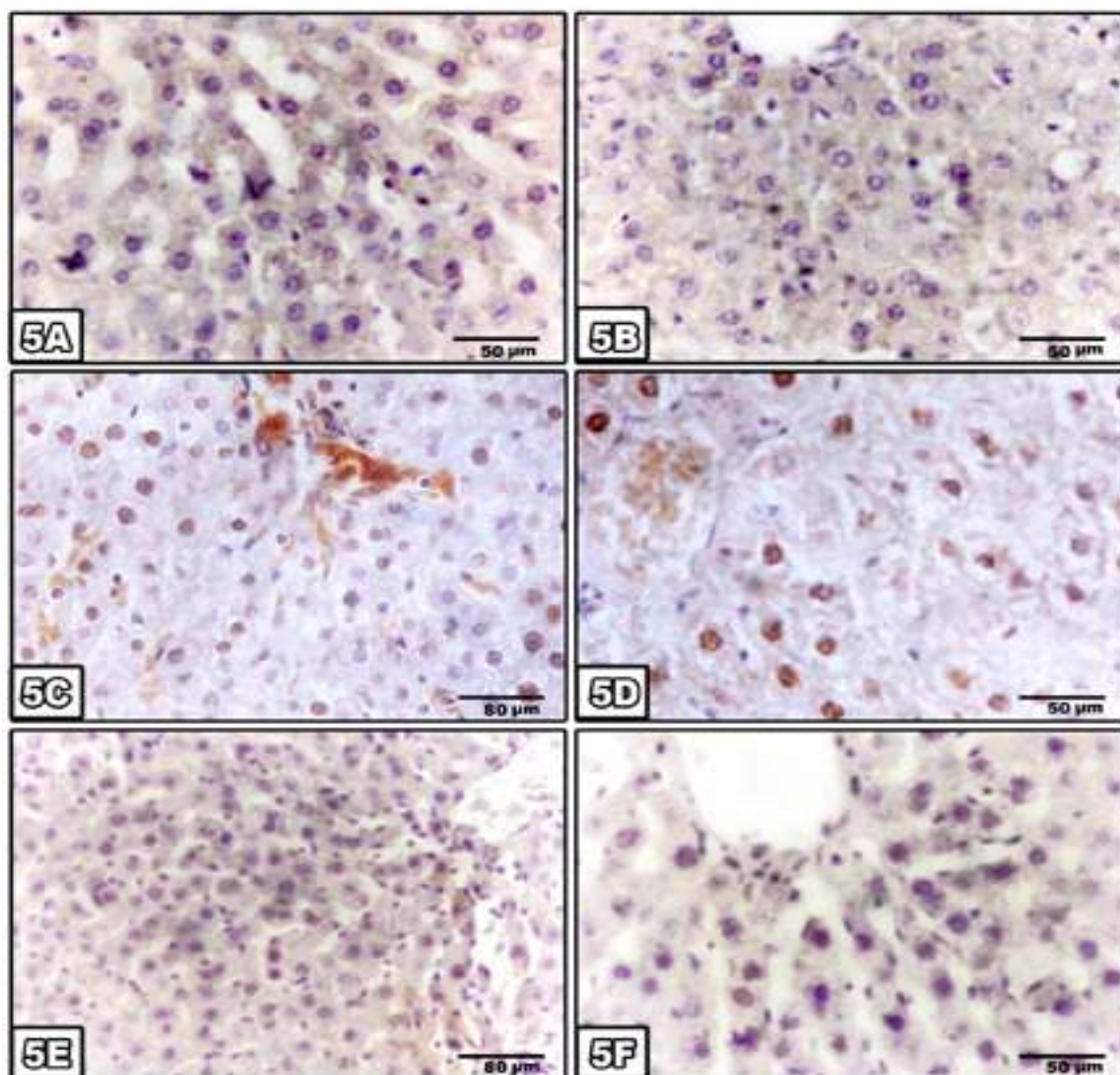
\*  $P < 0.001$ , compared to the control group

\*\*  $P \leq 0.001$  compared to the DMBA



**Figure 4:** Histochemical demonstration of the content and localization of polysaccharides (4A-4D) and total proteins (4E-4H) of liver sections of rats treated with GE and/or DMBA. Liver section of control rat (4A) showing strong PAS positive reaction and normal distribution of polysaccharides in the cytoplasm of the hepatocytes with glycogen flight phenomenon (arrow), liver section of GE-treated rat (4B), liver sections of DMBA injected rats (4C) displaying weak PAS positive reaction in most hepatocyte except the hepatocytes near the central vein show strong PAS positive, liver section of DMBA+GE treated group (4D) illustrating strong PAS positive reaction in the hepatocytes near the central vein. Liver section of control rat (4E) showing normal dense protein content with normal distribution of protein in all of the hepatocytes, liver section of GE-treated rat (4F), liver sections of DMBA injected rats (4G) displaying a marked decrease of protein content in the hepatocytes, liver section of DMBA+GE treated group (4H) illustrating slight increase of protein content in comparison with DMBA treated group.





**Figure 5:** Immunohistochemistry of PCNA in liver sections of rats treated with GE and/or DMBA. Liver section of normal control rat (5A), liver section of GE-treated rat (5B), liver sections of DMBA injected rats (5C,5D) displaying strong positively stained nuclei, liver sections of DMBA+GE treated group (5E,5F) illustrating that the positively-stained nuclei are markedly decreased in number, (Immunoperoxidase PCNA).

## REFERENCES

1. Cooke M, Denis A. Polynuclear Aromatic Hydrocarbons. In: A Decade of Progress. Butte, Columbus: Ohio, **1988**.
2. Christou M et al. Cytochromes CYP1A1 and CYP1B1 in the rat mammary gland: cell specific expression and regulation by polycyclic aromatic hydrocarbons and hormones. *Mol Cell Endocrinol* 1995; 115: 41–50.
3. Rowlands JC et al. Soy and whey proteins down regulate DMBA-induced liver and mammary gland CYP1 expression in female rats. *J Nutr* 2001; 131: 3281–3287.
4. Ma Q, Lu AY. CYP1A induction and human risk assessment: an evolving tale of *in vitro* and *in vivo* studies. *Drug Metab Dispos* 2007; 35: 1009–1016.
5. Dipple A, Bigger C. Mechanism of action of food associated polycyclic aromatic hydrocarbon carcinogenesis. *Mut Res* 1991; 259: 263-276.

6. Ajith TA et al. *Zingiber officinale* Roscoe prevents acetaminophen-induced acute hepatotoxicity by enhancing hepatic antioxidant status. Food Chem Toxicol 2007; 45: 2267–2272.
7. Ahmed RS et al. Protective effects of dietary ginger (*Zingiber officinales* Roscoe) on lindane-induced oxidative stress in rats. Phytother Res 2008; 22: 902–906.
8. Shukla Y, Singh M. Cancer preventive properties of ginger: A brief review. Food Chem Toxicol 2007; 45: 683–690.
9. Habib SHM et al. Ginger extract (*Zingiber officinale*) has anti-cancer and anti-inflammatory effects on ethionine-induced hepatoma rats. Clinics 2008; 63: 807–813.
10. Thomson M et al. The use of ginger (*Zingiber officinale* Roscoe) as a potential anti-inflammatory and antithrombotic agent. Prostaglandins Leukot Essent Fatty Acids 2002; 67: 475–478.
11. Kamtchouing P et al. Evaluation of androgenic activity of *Zinigiber officinale* and *Pentadiplandra bazeana* in male rats. Asian J Androl 2002; 4(4): 299-301.
12. Macejova D, Brtko J. Chemically-induced carcinogenesis: A comparison of 1-Methyl-1-nitrosourea, 7,12-Dimethylbenz(a)anthracene, Diethylnitroso-amine and Azoxymethan models (minireview). Endocr Regul 2001; 35: 53-59.
13. Weesner FM. General Zoological Microtechniques. Scientific Book Agency: Calcutta, 1968.
14. Masson PJ. AFIP Modification. J Tech Methods 1929; 12: 75-90.
15. Pearse AGE. Histochemistry, Theoretical and Applied, 4th ed.; Vol. 2, Churchill, Ltd.: London, 1985.
16. Mazia D et al. The cytochemical staining and measurement of protein with mercuric bromophenol blue. Biol Bull 1953; 104: 57-67.
17. Mathivadhani P et al. Effect of *Semecarpus anacardium* Linn. nut extract on mammary and hepatic expression of xenobiotic enzymes in DMBA-induced mammary carcinoma. Environ Toxicol Pharmacol 2007; 23: 328–334.
18. Devlin TM. Textbook of Biochemistry: With clinical correlations, 4th ed.; Wiley & Sons: New York, 1997; pp. 553.
19. Masuda Y et al. Anti-oxidant properties of gingerol related compounds from ginger. Biofactors 2004; 21: 293-296.
20. Edington G, Gilles H. Pathology in the Tropics. 2nd ed.; William Clowes & Sons: London, 1976.
21. Kondo Y. Pathology of early hepatocellular carcinoma and preneoplastic lesions in the liver. In: Liver Cancer. Okuda K, Tabor E, Eds.; Churchill Livingstone: New York, Tokyo, 1997.
22. Farag-Allah AM, Abdel-Dayem SM. Biochemical, histological and ultrastructural studies on the protective effect of vitamin A against the carcinogenic effect of 7,12-dimethylbenz(a)anthracene (DMBA) on the liver of albino rats. Egypt J Zool 2001; 37: 335-368.
23. Sadek I et al. Chemopreventive effects of cabbage on 7,12 dimethylbenz(a)anthracene-induced hepatocarcinogenesis in toad (*Buffo viridis*). J Nut Sci Vitaminol Tokyo 1995; 41(1): 163-168.
24. Abdel Meguid N et al. Ultrastructural criteria that prove the similarities between amphibian and human tumours. Oncology 1997; 54(3): 258-263.
25. Sakr SA. Pyrethroid inhalation induced hepatotoxicity in albino rats. Oxford Res Forum J 1999; 1(1): 27-31.
26. Purohit V, Brenner DA. Mechanisms of alcohol-induced hepatic fibrosis: a summary of the Ron Thurman symposium. Hepatology 2006; 43: 872–878.
27. Carter EA et al. Lysyloxidase and collagenase in experimental acute and chronic liver injury. Gastroenterology 1982; 82:526-34.
28. Nemcsok B, Halasy K. Electron analysis of cytopathological effect of pesticides in the liver, kidney and gill tissues of crab. Acta Biol Szeged 1986; 33: 69-91.
29. Attia A. Effect of indomethacin on the co-carcinogenicity of dietary fat in the Egyptian toad. PhD Thesis, Alexandria University: Egypt, 1998.
30. Wu XG et al. Anticarcinogenic effect of red ginseng on the development of liver cancer induced by diethylnitrosamine in rats. J Korean Med Sci 2001; 16: 61-65.
31. El-Banhawy MA et al. Histochemical studies on the effect of the anticoagulant rodenticide "brodifacoum" on the liver cells of rats. J Egypt Ger Soc Zool 1993; 12(C): 229-285.
32. Ismail MF et al. Ultrastructural study on the protective effect of ginger against the toxicity of 7,12 dimethylbenz[a] anthracene (DMBA) on the liver of albino rats. Egypt J Exp Biol 2009; 5: 199 –205.
33. Fukumasu H et al. Chemopreventive effects of *Paullinia cupana* Mart var. *sorbilis*, the guarana, on mouse hepatocarcinogenesis. Cancer Lett 2006; 233: 158-164.
34. Nakano A et al. Immunohistochemical studies on the expression of P-glycoprotein and p53 in relation to histological differentiation and cell proliferation in hepatocellular carcinoma. Hepatol Res 2003; 25: 158-165.

35. Chuang SE et al. Curcumin-containing diet inhibits diethylnitrosamine-induced murine hepatocarcinogenesis. *Carcinogenesis* 2000; 21(2): 331-335.
36. Lesko SA et al. Benzo(a)pyrene radicals and oxygen radical Involvement in DNA damage, cellular toxicity and carcinogenesis. In: Free radicals, lipid peroxidation and cancer. McBrien DCH, Slater TC, Eds; Academic Press: New York, 1982; pp. 401-420.
37. Childambraram N, Baradarajan A. Effect of dietary selenium on lipid peroxidation and glutathione peroxidase activity in rats with mammary tumors induced by 7, 12-dimethyl Benz[a]anthracene. *Med Sci Res* 1994; 22(4): 285-287.
38. Halliwell B. Anti-oxidants in human health and disease. *Ann Rev Nutr* 1996; 16: 33-50.
39. Hollander M et al. Dimethylbenzanthracene carcinogenesis in Gadd45a-null mice is associated with decreased DNA repair and increase mutation frequency. *Cancer Res* 2001; 61(6): 2487-2491.
40. Ames B. Dietary carcinogen and anti-carcinogens. *Science* 1983; 221: 1256-1264.
41. Sakamura F, Hayashi S. Constitution of the essential oil from rhizomes of *Zingiber officinale* Roscoe. *Nihon Nogei Kogakkaishi* 1978; 52: 207-211.
42. Nishimura O. Identification of the characteristic odorants in fresh rhizomes of ginger using aroma extract dilution analysis and modified multidimensional gas chromatography-mass spectrometry. *J Agric Food Chem* 1995; 43: 2294-2945.
43. Bartley J, Jacobs A. Effects of drying on flavour compounds in Australian-grown ginger (*Zingiber officinale*). *J Sci Food Agric* 2000; 80: 209-215.
44. Theunissen PH et al. PCNA expression in formalin-fixed tissue of NSCLC. *Histopathology* 1992; 20: 251-255.
45. Siddaraju MN, Dharmesh SM. Inhibition of gastric h<sup>+</sup>, k<sup>+</sup>, ATPase and *Helicobacter pylori* growth by phenolic oxidants of *Zingiber officinale*. *Mol Nutr Food Res* 2007; 51(3): 324-332.
46. Heeba GH, Abd-Elghany MI. Effect of combined administration of ginger (*Zingiber officinale* Roscoe) and atorvastatin on the liver of rats. *Phytomedicine* 2010; 17:1076-1081.
47. Toda S et al. Natural antioxidants III, antioxidative compounds isolated from rhizomes of *Curcuma longa*. *Chem Pharmacol Bull (Tokyo)* 1985; 33: 1725-1728.
48. Aeschbach R et al. Anti-oxidant actions of thymol, zingerone and hydroxytyrosol. *Food Chem Toxicol* 1994; 32:31-36.
49. Sekiwa Y et al. Isoaltion of novel glucosides related to ginger diol from ginger and their antioxidative activities. *J Agri Food Chem* 2000; 48: 373-377.
50. Ippoushi K et al. [6]-Gingerol inhibits nitric oxide synthesis in activated J774.1 mouse macrophages and prevents peroxynitrite-induced oxidation and nitration reactions. *Life Sci* 2003; 73: 3427-3437.
51. Radi R et al. Unraveling peroxynitrite formation in biological systems. *Free Radical Biol Med* 2001; 30: 463-488.
52. Kang LP et al. Effect of genistein and quercetin on proliferation, collagen synthesis and type I procollagen mRNA levels of rat hepatic stellate cells. *Acta Pharmacol Sci* 2001; 22: 793-796.
53. Mao YQ et al. Effect of quercetin on the signal pathway of TGFbeta1 in activated hepatic stellate cells. *Sichuan Da Xue Xue Bao Yi Xue Ban* 2004; 35: 802-805.
54. Surh YJ et al. Anti-tumor-promoting activities of selected pungent phenolic substances present in ginger. *Toxicol Oncol* 1999; 18: 131-139.
55. Surh YJ. Anti-tumor promoting potential of selected spice ingredients with antioxidative and anti-inflammatory activities: a short review. *Food Chem Toxicol* 2002; 40: 1091 -1097.
56. Hanahan D, Weinberg RA. The hallmarks of cancer. *Cell* 2000; 100: 57-70.