



Acute Myocardial Infarction -Rare Complication of Snake Bite: A case report

Dr. J.A. Vasanthakumar¹, Dr. N. Kalaisezhian¹, Dr. Manohari Ramachandran² and Dr. M.C. Vasif Mayan³

¹Senior Assistant Professor in Medicine, ²Associate Professor in Medicine and ³Post Graduate in Medicine, Govt. Mohankumaramangalam Medical College, Salem, India

Received: 17-08-2015 / Revised: 23-09-2015 / Accepted: 30-09-2015

ABSTRACT

Acute myocardial infarction (AMI) is a rare complication of snake bite with few reported cases in literature. Ischemic cardiac events, arrhythmias and cardiac tamponade rarely occur after viper bites. We report a case of inferior wall ST segment elevation myocardial infarction in a 43 year old previously healthy male following Russell's viper bite which is an extremely rare presentation.

Keywords: Snake bite, Russell's viper, Myocardial Infarction, Acute kidney injury, Rhabdomyolysis, Anti snake venom

CASE HISTORY

A previously healthy 43 year old male with no history of cardiac disease or cardiac risk factors was brought to the emergency department 6hrs after a snake bite in his right foot just below the medial malleolus. The dead snake also was brought and identified as Russell's viper.

Patient was irritable and drowsy and had progressive cellulitis in the right lower limb upto 5cm below the knee joint with a whole blood clotting time > 20minutes at admission. Fang marks were identified in his right foot just below the medial malleolus. Patient additionally complained of chest pain for 1 hour duration during his transit to the hospital which was felt as a retrosternal heaviness on the chest associated with profuse sweating.

On examination, Pulse rate was 110/mt low volume thready, blood Pressure was 70/40 mm in the right upper limb. Other system examinations were within normal limits. ECG revealed ST segment elevation in leads II, III and avF with reciprocal changes in leads I and avL suggestive of acute inferior wall myocardial infarction (Fig1).He was rapidly resuscitated with fluids, intramuscular anti tetanus serum, and intravenous infusion of 8 vials of polyvalent antisnake venom. Adequate wound care and management of cellulitis was given. Despite the fluid resuscitation, his Blood pressure did not improve and was started on inotropes. Patient had

an episode of blood tinged vomiting for which 4 units of fresh frozen plasma was transfused. Thrombolysis, anticoagulants and antiplatelets were not considered due to prolonged 20 min whole blood clotting time and bleeding manifestation.

CK-MB was 83 IU/L(Normal upto 25IU/L). The CPK levels was 1216IU/L (Normal 25-190 IU/L). Baseline urea levels at admission was 19mg/dl with creatinine of 0.9mg/dl. Echocardiogram revealed mild hypokinesia of the inferior wall with mild Left Ventricular dysfunction.

Due to frequent hypotension and prolonged 20 min WBCT, Anti snake venom therapy was repeated with 8 more vials. His Blood pressure was dropping frequently but responded to Subcutaneous Adrenalineboluses and IV fluid boluses and IV inotropes were stepped up.

Following treatment, the patient's symptoms improved and chest pain gradually subsided. The ST segment changes started to resolve following the Antisnake venom administration (Fig 2).Hemodynamic variables stabilised with patient maintaining blood pressure above 120/70mm and Clotting time was found to be 11 minutes 16hours after treatment. Renal function test was initially normal but the creatinine was found to be 3.2mg/dl and 4.2mg/dl on the 2nd and 3rd day respectively. Serum LDH was found to be 950IU indicative of rhabdomyolysis. Fluid management measures were

stepped up and the acute kidney injury resolved on day 7 and the serum urea and creatinine values were 23mg/dl and 1mg/dl respectively. Cellulitis resolved with conservative measures and The ECG changes reverted back to normal and the patient was safely discharged from the hospital with advice for regular follow up.

DISCUSSION

Acute myocardial infarction (AMI) is a rare complication of snake bite with few reported cases in literature. The diagnosis of myocardial infarction was confirmed by a characteristic retrosternal chest pain, typical electrocardiographic changes, and elevated CK-MB levels. Viper bites are notorious for local and systemic complications including local tissue necrosis, hemolysis and hemorrhagic complications, nephrotoxicity, coagulation abnormalities and neurological complications. A study conducted in Nigeria involving 108 snake bite patients found that more than 60% patients had hemodynamic and electrocardiographic abnormalities, but significant cardiac enzyme elevation occurred in only one patient.^[2]

The mechanism by which myocardial ischemia or infarction occurs is not known clearly. Possible mechanisms are, disseminated intravascular coagulation³ causing thrombus⁴ formation in

coronaries and direct vasculitis by snake venom causing an infarction. Some snakes have sarafotoxins⁵ which cause coronary vasoconstriction. Coronary spasm⁶ due to endothelins released by snake bite is also considered to be a possible mechanism.

Other mechanisms suggested are hypovolemic shock due to bleeding, anaphylactic shock, hypercoagulability in consumption coagulopathy, hyperviscosity secondary to hypovolemia induced hemoconcentration, direct cardiotoxic effect on myocardium.

The importance of the case report is to highlight upon the fact that physicians should be aware of this potentially life-threatening complication of viper bite and take immediate steps for its recognition and management

CONCLUSION

This unique case provides evidences for rapid development of ST elevation myocardial infarction following a possible Russell's viper bite. Pathophysiology of myocardial ischemia in snakebites needs to be explored through careful documentation of clinical condition and thorough investigation of the snakebite victims.

Fig 1 : ECG On Admission - Shows ST elevation in inferior Leads and reciprocal change of ST depression in Anterior leads

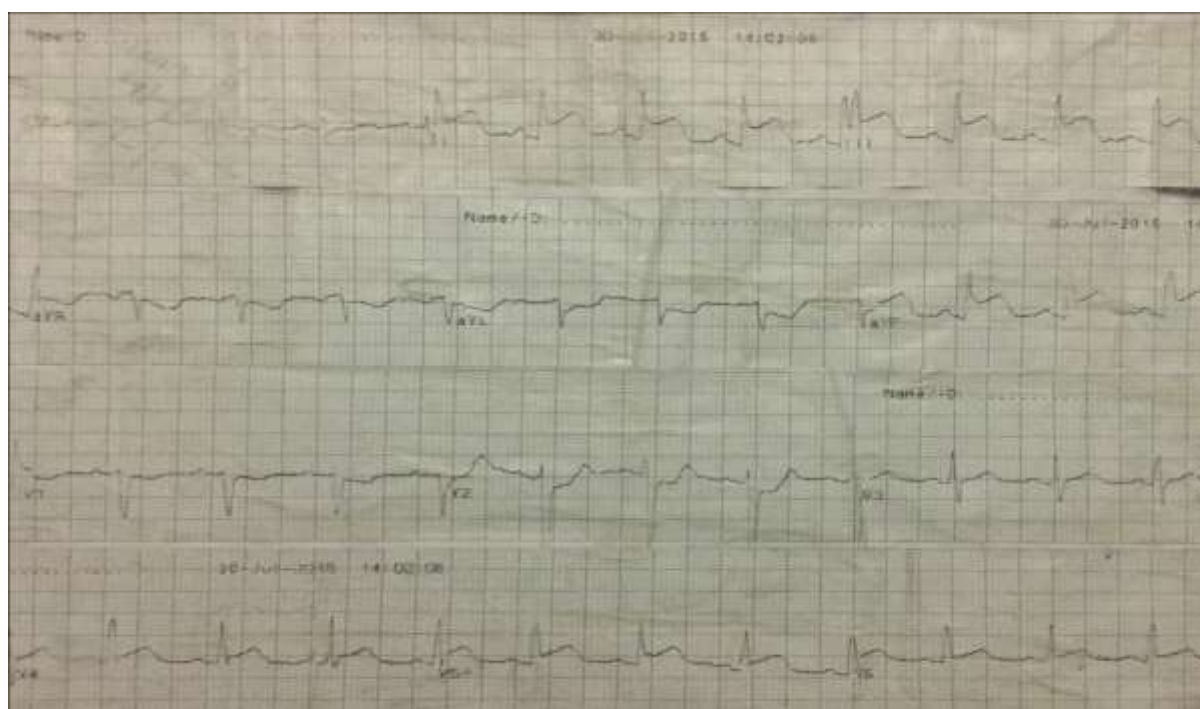
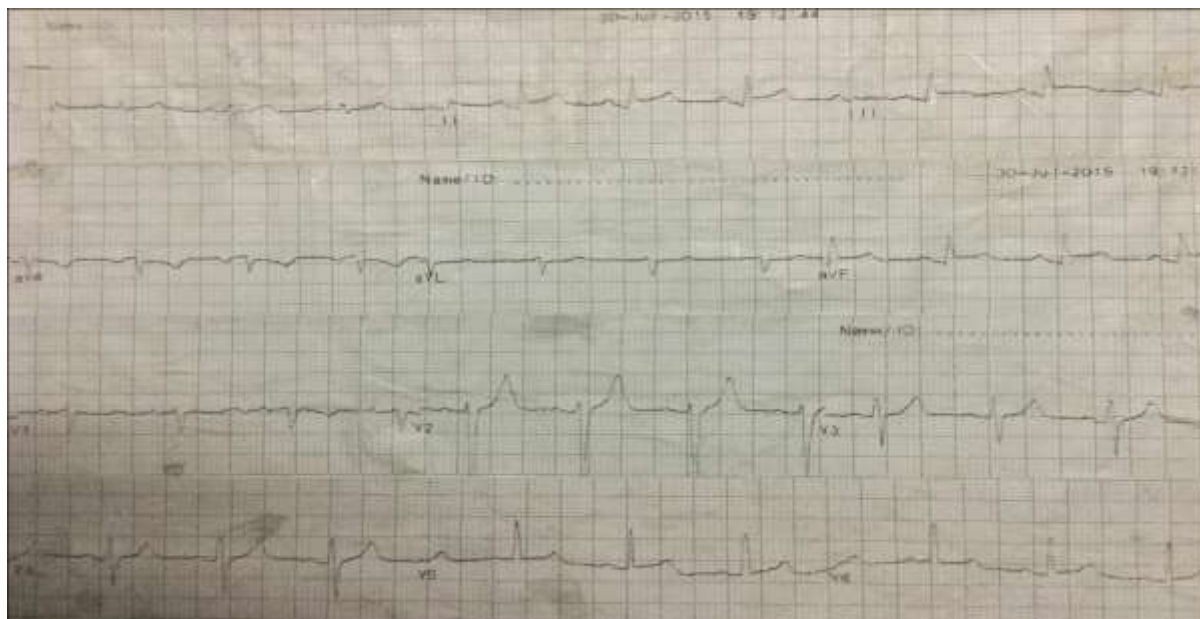


Fig 2 ECG after Administration of Antisnake Venom – ST elevation reverted to normal baseline.



REFERENCES

1. Phillips RE, Theakston RD, Warrell DA, Galigedara Y, Abeysekera DT, Dissanayaka P, *et al.* Paralysis, rhabdomyolysis and haemolysis caused by bites of Russell's viper (*Viperarussellipulchella*) in Sri Lanka: Failure of Indian (Haffkine) antivenom. *Q J Med* 1988;68:691-715.
2. Karaye KM, Mijinyawa MS, Yakasai AM, Kwaghe V, Joseph GA, Iliyasu G, *et al.* Cardiac and hemodynamic features following snakebite in Nigeria. *Int J Cardiol* 2012;156:326-8.
3. Copley AL, Banerjee S, Devi A. Studies of snake venoms on blood coagulation. *Thromb Res* 1973;2:487-508.
4. Blondheim DS, Plich M, Berman M, Khair G, Tzvig L, Ezri J, *et al.* Acute myocardial infarction complicating viper bite. *Am J Cardiol* 1996;78:492-3.
5. Wollberg Z, Bdolah A, Kochva E. Cardiovascular effects of mammalian endothelins and snake venomsarafotoxins. In: Abrahams S, Amitai G, editors. *Calcium Channel Modulators in Heart and Smooth Muscle*. Deerfield Beach, FL: VCH; 1990. p. 283-99.
6. Maheshwari M, Mittal SR. Acute myocardial infarction complicating snake bite. *J Assoc Physicians India* 2004;52:63-4