



The cadaveric study of the lateral position of the external carotid artery

Lakshmi gayathri G B^{1*}, Vino Victor Jesudas²

¹Assistant Professor of Anatomy, ²Director and Professor of Anatomy, Madurai Medical College, Madurai, Tamilnadu, India – 625020

Received: 15-06-2019 / Revised Accepted: 31-07-2019 / Published: 02-08-2019


ABSTRACT

During regular educational dissections of 20 cadavers irrespective of sex, in the Institute of Anatomy of Madurai Medical college, a rare anatomic variant was encountered at the level of the right carotid triangle of a human adult cadaver. The variant was unilateral. On that side the common carotid artery bifurcated at the level of the upper border of the thyroid cartilage. The External carotid artery was posterolateral to the Internal carotid artery and the anterior branches of the former (Superior thyroid, Lingual and Facial arteries) initially crossed over the Internal carotid artery before continuing with a normal anatomical course. The possibility of an inverse disposition of the Internal and External carotid arteries is a rare anatomical variant. Such a variant poses a challenge for the Vascular Surgeons when performing arterial ligatures in the carotid triangle for various procedures like carotid Endarterectomy, chemotherapeutic drug instillation, arterial embolisation etc, to avoid any vascular or nerve damage. Hence this study aims at presenting the prevalence of disposition of the Internal and External carotid artery within the carotid triangle, which helps the Surgeons when performing the various arterial procedures.

Keywords: Carotid triangle, External carotid artery, Internal carotid artery, Endarterectomy, Embolisation

Address for Correspondence: Dr. Vino Victor Jesudas, Director and Professor of Anatomy, Institute of Anatomy, Madurai Medical College, Madurai, Tamilnadu, India; E-mail: vinovictor@rocketmail.com

How to Cite this Article: Lakshmi gayathri G.B., Vino Victor Jesudas. The cadaveric study of the lateral position of the external carotid artery. World J Pharm Sci 2019; 7(8): 82-85.

This is an open access article distributed under the terms of the Creative Commons Attribution-NonCommercial-ShareAlike 4.0 International License, which allows adapt, share and build upon the work non-commercially, as long as the author is credited and the new creations are licensed under the identical terms. 

© 2019 World J Pharm Sci

INTRODUCTION

Knowledge of the position of the External carotid artery (ECA) in relation to the internal carotid artery beyond its origin within the carotid triangle, imparts a greater significance in many surgical implications. The ECA arises from the bifurcation of the Common carotid artery (CCA), lateral to the upper border of thyroid cartilage, level with the Intervertebral disc between the third and fourth cervical vertebrae^[1]. At its origin, it lies in the carotid triangle and is anteromedial to the internal carotid artery (ICA). As it ascends it comes to lie anteriorly and then lateral to ICA, before the later enters into the cranial cavity^[1]. The Superior thyroid, Lingual and Facial arteries arise from the anterior surface of the ECA, while the Occipital and Posterior auricular arteries originate from its posterior surface. All these branches of external carotid artery originate medial to ICA, within the carotid triangle.

The anatomic characteristic of interest in this study was the variable disposition of the External carotid artery and Internal carotid artery in the carotid triangle. Also the study examined the relative coursing of the branches of ECA in relation to ICA. This characteristic interacts with many pathological mechanisms and surgical managements.

The importance in knowing the possibility of the inverse position of ECA and ICA becomes mandatory in procedures like Carotid endarterectomy. Surgeons should consider such anatomic details² in the selection and application of proper surgical therapy during the treatment of head and neck tumors or Carotid tumours.

MATERIALS AND METHODS

Twenty properly embalmed, formalin preserved cadavers were taken for this study. The present study was carried out during the years of 2016-2018, in the department of Anatomy of Madurai Medical College, Madurai (TN). Meticulous dissection was carried out in the carotid triangle of the Head and Neck region, to detect the bifurcation of Common Carotid artery into Internal and External carotid artery. The position of ECA with respect to the ICA after the CCA bifurcation was noted in 40 heminecks of the cadavers. The origin and course of the anterior branches of ECA in relation to ICA within the carotid triangle were also noted. The required data was properly photographed and their frequencies were calculated.

RESULTS

During the routine dissection of the twenty formalin preserved cadavers in the department of Anatomy of Madurai Medical College, Madurai, a lateral disposition of the External carotid artery

relative to the Internal carotid artery, after originating from the bifurcation of Common carotid artery, was observed on the right side carotid triangle in one cadaver. ICA was medially placed within the carotid triangle and the external carotid artery was presented posterolateral to ICA. Bifurcation of CCA occurred at the level of upper border of the thyroid cartilage. The anterior branches of the ECA, i.e Superior thyroid, Lingual and Facial arteries originated from the usual levels of ECA, coursed from lateral to medial side. During their course, they were crossing anterior to the ICA, after which all the anterior branches followed a normal course. The hypoglossal nerve was crossing from lateral to medial side, first anterior to ECA and then the ICA to follow its normal course. The left side of the same cadaver was found to have the posteromedial ECA relative to ICA, with the normal origin and coursing of its anterior branches. All the other cadavers had the normal relation of ECA with ICA on either sides.

DISCUSSION

The probability for this anatomic variation, would be due to the excessive medio- lateral migration of ECA during the embryogenesis of Arterial Arches. It might also happen due to age related factors, secondary to neck elongation or due to the excess tortuosity produced by atherosclerotic carotid arteries^[2].

Handa J (1972) has credited the anatomist Hyrtl for his first description of this anomaly in 1841. Earlier reviews with regard to this variation in cadavers has yielded only a few reports. Rusu M Cin 2006 reported a posterolateral ECA, which was right sided in a cadaver, during their routine dissection. Also Bailey M A in 2007 identified two cadavers having lateral ECA on their right sides, during the dissection for his project study. Both reports has stated right sided variation and the anterior branches of ECA crossed over the ICA, before following their normal course. The variation in the present study was similitative to their observations. Annette K (2015) was the first to describe the rare variation of lateral ECA with linguofacial trunk, in the right carotid triangle of a Caucasian cadaver. Such linguofacial trunk crossing and obscuring the ICA will greatly limit the access of approach to ICA.

In the present study, an incidence of 2.5%, of the lateral position of External carotid artery with respect to the Internal carotid artery after its origin from carotid bifurcation, was noted.

Despite very less prevalence of the lateral ECA in cadaveric reports, Angiographic and Ultrasound studies has suggested their incidence to be of 4-12.3% , most often on the right side^[7]. In a study by

Prendes J L (1980), an anatomic variant in the position of ECA at the carotid bifurcation was noted, where it was lateral and posterior to ICA in 5.3% patients, studied by Doppler Ultrasound and contrast Angiography^[9]. According to Bussaka H (1990), lateral position of the external carotid artery was seen in 17 cases (4.3%), out of which 13 cases were on the right side and 4 cases were on the left side. An unusual case of peripheral hypoglossal nerve palsy, caused by lateral position of the external carotid artery and an abnormally high carotid bifurcation has been reported^[11].

The external carotid artery (ECA) is anatomically complex, providing the blood supply to the extracranial head and neck regions. Despite this significant arterial network, ECA intervention is almost exclusively performed in the form of transcatheter embolisation for hypervascular tumours, epistaxis and trauma^[12]. In the present study the variation may lead to vascular injuries when performing ligatures on the anterior branches during head and surgeries, because they perform a different course by initially crossing the Internal carotid artery. Any injury to the Internal carotid

artery during such ligatures may become fatal which compromises the blood supply to the brain. Hence, Surgeons must keep in mind of the possibility of an inverse disposition of the ICA and ECA, when performing arterial ligatures in the carotid triangle, to avoid damage to the ICA or for hemorrhagic accidents. Also hypoglossal nerve injury is possible, since it crosses the external carotid artery first within the carotid triangle, during head and neck surgeries like thyroidectomy, laryngectomy.

In addition during preoperative selective angiograms, the Radiologists need to be aware of encountering such arterial variations. Carotid endarterectomy of cervical ICA, is the mainstay treatment in atherosclerotic plaque. Due to the inverse relation of the ECA and ICA, the anterior branches of ECA coursing over the ICA may hinder the adequate exposure of the carotid arteries for cross clamping, during removal of the plaque^[13]. Hence consideration of this important variant is mandatory to carry out endarterectomy and to minimize postoperative complications.



Figure 1: Posterolateral disposition of ECA

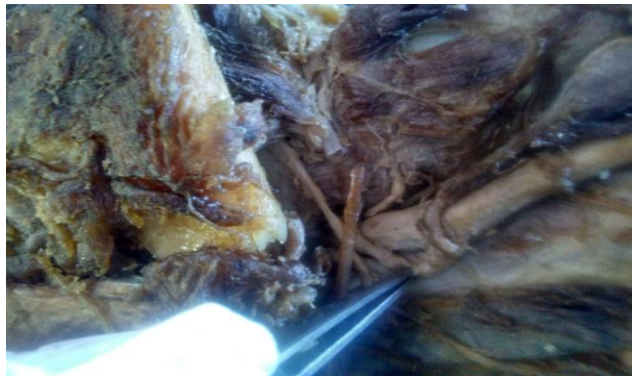

Figure 2: Anterior branches of ECA crossing ICA in carotid triangle (right)

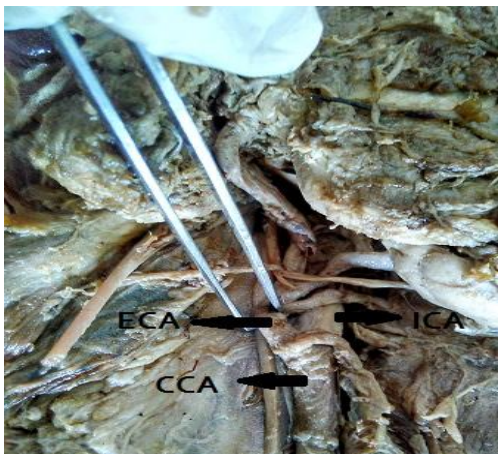

Figure 3: Hypoglossal nerve crossing ECA and then ICA

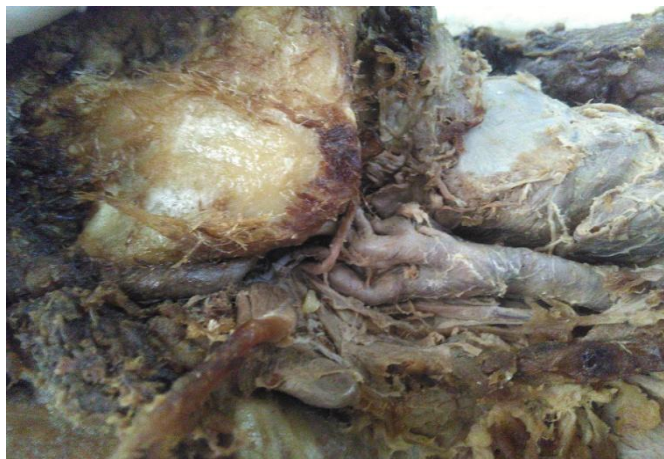

Figure 4: Normal position of ECA (posteromedial)

CONCLUSION

This case study describes the presence of the lateral External carotid artery on the right side of the carotid triangle in a cadaver. Such malformations are rare and is important to know about its possibility which may pose danger during neck surgeries, interventional procedures or in many chemotherapeutic drug instillations for head and neck tumours⁴. Surgical anatomy of the carotid triangle is complex but important for many different clinical and surgical applications. Anatomically it should not be seen as the disposition between ICA and ECA only but rather in conjunction with other important anatomic structures in the related area, including cranial nerves. It may lead to serious misinterpretation of the clinical diagnosis, when such variation is

presented. Treatment of carotid sinus syndrome and carotid body tumors also implies thorough understanding and knowledge of bifurcation of Carotid artery and the relative positions of the Internal and External carotid artery anatomy. Detailed anatomic knowledge of ECA branches and their coursing in the carotid triangle is important for radiologic interventions including embolization and chemoembolization for head and neck tumors^[14].

To conclude lateral External carotid artery is not as uncommon as before. Hence Vascular Surgeons should be aware of this variant, so that appropriate surgical techniques can be implemented to allow safe surgeries avoiding unnecessary nerve or vascular injuries.

REFERENCES

1. Standring S Gray's anatomy. The anatomical basis of clinical practice. 41st edition; Elsevier, Churchill Livingstone: Edinburgh, London, New York, 2016; 451- 454.
2. Desai B, Toole JF. Kinks, coils, and carotids: a review. *Stroke*. 1975; 6:649-653.
3. Handa J et al. Lateral position of the external carotid artery. Report of a case. *Radiology*. 1972;102:361-362.
4. Rusu MC et al. A rare anatomic variant: the lateral position of the external carotid artery. *Oral Maxillofacial Surg*. 2006;35(11):1066-1067.
5. M.A. Bailey et al. Lateral External Carotid Artery: Implications for the Vascular Surgeon. *European Society for Vascular Surgery*. 2007; 22-24.
6. Kirchgessner A. Lateral external carotid artery and linguofacial trunk: a rare anatomic variant . *MOJ Anat & Physiol*. 2015;1(1):1-3.
7. Teal JS et al. Lateral position of the external carotid artery: a rare anomaly? *Radiology*. 1973;108: 77-81.
8. Prendes JL et al. Anatomic variations of the carotid bifurcation affecting doppler scan interpretation. *J Clin Ultrasound*. 1980;8:147-150.
9. S. B. Rao et al. Unusual position of external carotid artery: a case report. *Indian J Plast Surg*. 2005; 38 : 2
10. Bussaka H et al. Lateral position of the external carotid artery. *Rinsho Hoshasen*. 1990;35(9):1061-1063.
11. Ueda S et al. Peripheral hypoglossal nerve palsy caused by lateral position of the external carotid artery and an abnormally high position of bifurcation of the external and internal carotid arteries—a case report. *Stroke*. 1984;15:736-9.
12. Tony P. Smith. Embolization in the External Carotid artery. *J Vasc Interv Radiol*. 2006; 17:1897-1913.
13. Adamantios M. et al. Anatomical Considerations on Surgical Anatomy of the Carotid Bifurcation. *Anatomy Research International*. 2016; Article ID 6907472: 8 pages.
14. Hayashi N et al. Endo S surgical anatomy of the cervical carotid artery for carotid endarterectomy. *Neurol Med Chir*. 2005; 45: 25-30