



Clinicopathological Analysis of Hysterectomies in a Tertiary Care Hospital

Prageetha K¹ and Dr. Srinivasan V^{2*}

¹Second MBBS and ²Associate Professor, Department of Pharmacology, Saveetha Medical College & Hospital, SIMATS, Chennai-602105, India

Received: 02-08-2019 / Revised Accepted: 01-09-2019 / Published: 02-09-2019

ABSTRACT

Aim: The aim of this study was to find out the common type of surgery performed, common age group affected, clinical presentation of the cases and the different clinical indications and its corresponding histopathological diagnosis for hysterectomy and to correlate them.

Materials and Methods: A retrospective study involving 67 cases undergoing hysterectomy for clinically benign conditions were included over a period of 7 months in the department of Obstetrics and Gynaecology in a tertiary care centre. All women undergoing both vaginal and abdominal hysterectomy were included in this study. Detail clinical data, indications for hysterectomy, type of surgeries were recorded and the specimen stored in formalin was sent for histopathological analysis. Histopathological reports were collected from the department of Pathology and the data were compiled and analysed.


Results: Common age group affected belonged to 40-49 years [58.2%]. Abnormal uterine bleeding was the common presentation [52.24%]. Frequent indication for hysterectomy was fibroid uterus [50.75%]. The major route of surgery was Total Abdominal Hysterectomy [74.63%]. Leiomyoma was the commonest pathology [53.73%] in the histopathology report and the correlation between histopathology diagnosis and the clinical indication was up to 94.44%.

Conclusion: The commonest clinical presentation is abnormal uterine bleeding and fibroid uterus is the frequent indication of hysterectomy, the common type of surgery is total abdominal hysterectomy and the common age group affected is between 40-49. The clinicopathological correlation between the clinical indication and the histopathological report is high thus proves that the histopathological analysis is highly essential to confirm and prove the clinical diagnosis. Hence the specimens after procedure must be subjected to histopathology examination to confirm the absolute pathological diagnosis.

Keywords: Hysterectomy, Fibroid Uterus, Leiomyoma, Clinicopathological Correlation

Address for Correspondence: Srinivasan. V, Associate Professor, Department of Pharmacology, Saveetha Medical College & Hospital, SIMATS, Chennai-602105, India; **E-mail:** dr.seeni23@gmail.com

How to Cite this Article: Prageetha K and Dr. Srinivasan V. Clinicopathological Analysis of Hysterectomies in a Tertiary Care Hospital. World J Pharm Sci 2019; 7(9): 132-136.

This is an open access article distributed under the terms of the Creative Commons Attribution-Non Commercial-Share A like 4.0 International License, which allows adapt, share and build upon the work non-commercially, as long as the author is credited and the new creations are licensed under the identical terms. 

INTRODUCTION

Hysterectomy, surgical removal of the uterus is the second commonest major gynaecological surgery in both the pre and postmenopausal women all over the world. Charles Clay first performed the total abdominal hysterectomy in 1929. Hysterectomy may also involve removal of the cervix, ovaries, fallopian tube. oophorectomy, removal of one or both the ovaries is frequently done together with hysterectomy. The procedure is usually elective. The procedure is highly useful in certain gynaecological indications like fibroid uterus, prolapse of uterus, adenomyosis, endometriosis, cervical or endometrial pathology. Depending on the indications the type of surgery is carried out, it can be abdominal or vaginal where abdominal hysterectomy is the commonest route of surgery. Vaginal Hysterectomy [VH] is the carried out in prolapse uterus or sometimes in non-descent and is called as Non-Descent Vaginal Hysterectomy [NDVH]. Abdominal hysterectomy can be done either by open or laparoscopy and laparoscopic hysterectomy can be either Total Laparoscopic Hysterectomy [TLH] or Laparoscopy Assisted Vaginal Hysterectomy [LAVH].

Abdominal procedure may Total Abdominal Hysterectomy [TAH]. Depending upon the indications the route of the procedure is decided. The hysterectomy specimen is sent for histological examination. Histopathological data confirms and justifies the clinical diagnosis¹. Clinical presentations are different in different cases but investigation and histopathology report confirm the provisional diagnosis. Final diagnosis and further management are based on the histopathology findings. The specimen may also have various pathological findings hence in such case the most impact finding is taken in this study². This study aims in finding the common rote of surgery performed, the common age group affected, the clinical presentations of hysterectomy and the different clinical indications and its corresponding histopathological diagnosis of hysterectomy and to correlate the relationship between clinical indications and the histopathological diagnosis³.

MATERIAL AND METHODS

This study is retrospective and it was carried out in the department of Obstetrics and Gynaecology,

Saveetha Medical College and Hospital, Tamil Nadu. All women undergoing abdominal and vaginal hysterectomy were included in this study. Hysterectomy of obstetrics indications and malignant cases were excluded. Information and data of all hysterectomies performed for benign gynaecological conditions between June 2018 to January 2019 were taken. Patient's clinical data, ultrasound diagnosis, biopsy reports were collected. The hysterectomy specimen was stored in formalin and sent for histological examination. Histopathology reports were collected from the department of Pathology for statistical analysis.

RESULTS

About 67 hysterectomies were performed during the study period, out of which 50 was TAH, 16 was VH, and 1 was LAVH cases. Out of 16 VH cases, 15 were for genital prolapse and 1 case were NDVH (Table 1). Elective surgery is the procedure for all hysterectomies. Age group of the patients was between 32 to 80 years. Major no of case [58.21%] was in the age group of 40-49 years.(Table 2)

About 35 cases [52.24%] cases had Abnormal Uterine Bleeding [AUB] with or without pain lower abdomen(Table 3) .17 [25.37%] cases had pain lower abdomen with or without white discharge per vagina and 15 [22.39%] complained of mass descending per vagina with or without associated pain or discharge.(Fig 1) Common Indications of hysterectomy were leiomyoma 34[50.75%], genital prolapse 15[22.39%], adenomyosis 6[8.95%], ovarian cyst 2[2.98%], chronic cervicitis 9[13.43%], cervical dysplasia 1[1.49%].(Table 4, Fig 2)

Histopathology study presented leiomyoma 33[49.25%], adenomyosis 4 [5.97%], benign ovarian cyst 2[2.98%], cervical dysplasia 1[1.49%], benign endometrial pathology 1 [1.49%], cervicitis 8[11.94%].(Table 5). Multiple abnormal histopathological findings were common in many specimens and in such cases the prominent histopathological finding was taken for statistical analysis to avoid repetition. Clinicopathological correlation was done on all the specimens included in the study. (Table 6)

Table 1: Type of Hysterectomy

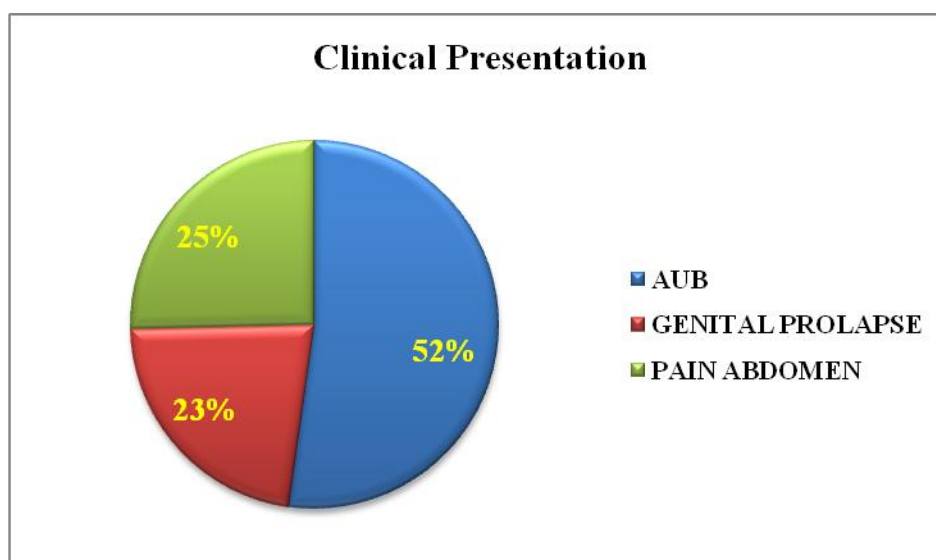
S.No	Type of Surgery	No. of Case [N=67]	Percentage of Cases%
1.	TAH-Total Abdominal Hysterectomy	50	74.63%
2.	VH-Vaginal Hysterectomy	16	23.88%
3.	LAVH-Laparoscopy Assisted Vaginal Hysterectomy	1	0.15%

Table 2: Age Distribution of Cases

S.No	Age Group In Years	No. of Cases [N=67]	Percentage of Cases%
1.	30-39	15	22.39%
2.	40-49	39	58.21%
3.	50-59	10	14.92%
4.	>/=60	3	4.48%

Table 3: Clinical Presentation

S.No	Clinical Presentation	No. of Cases [N=67]	Percentage %
1.	AUB+/- pain abdomen	35	52.24%
2.	Genital prolapse	15	22.39%
3.	Pain abdomen +/- white discharge per vagina	17	25.37%

Fig 1: Clinical Presentation of the Cases**Table 4: Indications for Hysterectomy**

S.No	Indications	No. of Cases [N=67]	Percentage %
1.	Fibroid	34	50.75%
2.	Prolapse	15	22.39%
3.	Adenomyosis	6	8.95%
4.	Chronic cervicitis	9	13.43%
5.	Ovarian cyst	2	2.98%
6.	Cervical dysplasia	1	1.49%

Table 5: Histopathology Report

S.No	HPE	No. Of Cases [N=67]	Percentage %
1.	NAD	18	26.86%
2.	Leiomyoma	33	49.25%
3.	Adenomyosis	4	5.97%
4.	Benign Ovarian Cyst	2	2.98%
5.	Cervicitis	8	11.94%
6.	Benign Endometrial Pathology	1	1.49%
7.	Cervical Dysplasia	1	1.49%

Fig 2: Indications for Hysterectomy

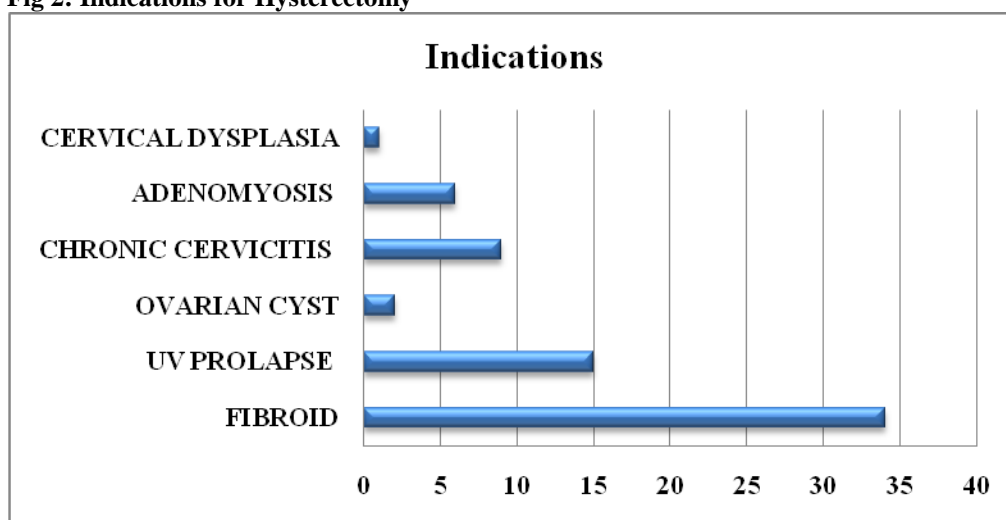


Table 6: Clinicopathological Correlation

S.No	Indication	Cases N=67	HPE	Clinicopathological Correlation %
1.	Leiomyoma	34	33	97.06%
2.	Adenomyosis	6	4	66.67%
3.	Ovarian cyst	2	2	100%
4.	Chronic cervicitis	9	8	88.89%
5.	Cervical dysplasia	1	1	100%

DISCUSSION

Hysterectomy, surgical removal of uterus is the major surgery done in case of much gynaecological disease. This study involves both premenopausal and postmenopausal women. Cases with obstetrics indications and malignant cases were excluded in this study. This surgery may also indulge in many complications as it affects morbidity, mortality and economic burden to the family. The surgery has its own physical, economic, sexual and medical significance to the women hence the surgery is performed only on highly indicated circumstances as it involves in the removal of reproductive organ of the female. So clinical indication is highly essential to carry out this procedure. Depending upon the disease and the expertise of the surgeon the route and type of surgery is decided. The indication of surgery expresses the widespread of the disease in the institution and in the locality. Histopathological analysis is essential and mandatory for the confirmation of the clinical diagnosis and hence all the hysterectomy specimens were subjected to histopathological examinations following the surgery⁴. The age group of the patients involved in this study was 32 to 80 years with frequent number of cases [58.21%] being in 40-49 years of age group. Only benign cases were taken. No obstetrics hysterectomy was included in this study. The common route of surgery is total abdominal hysterectomy [74.63%]. The frequent clinical presentation was Abnormal

uterine bleeding [52.24%], the common clinical indication involved is fibroid uterus [50.75%] and the common histopathological finding is leiomyoma [49.25%] and the clinicopathological correlation was up to 97.06% in this study.

Basanta Manjari Hota et al.,2018⁵ study on 232 cases shows AUB as the common clinical presentation [59.48%], TAH was the common route of surgery [71.12%, 40-49 years was the common age group [52.165], fibroid was the common indication [39.22%], leiomyoma was the common histopathological finding, the clinicopathological correlation was up to 98% same as our present study.

Dr.Vandhana Gangadharan et al.,2016⁶ study on 318 cases shows 40-49 [41.8%] is the common age group involved, abdominal hysterectomy is the common route of surgery [72.9%], fibroid uterus is the common clinical diagnosis [39.3%], Leiomyoma [41%] is the common histopathological diagnosis and the clinicopathological diagnose was up to 98%.

Jha R et al., 2006¹ study shows leiomyoma as the commonest [24.9%] indication for hysterectomy and the frequent pathology on histopathology report was leiomyoma [27.1%].

A Ebinesh et al.,2015⁸ study on 141 abdominal hysterectomy cases showed major age group of

patients affected was between 41-50 years [56%], major clinical presentation was AUB [63%] and leiomyoma was the repeated pathology [40.6%] on histopathology report

Shergill SK et al.,2002² study on 100 hysterectomy cases showed the major age group involved was between 31-50 years, the frequent clinical presentation is AUB [66%], commonest indication of hysterectomy was fibroid uterus [34%], commonest pathology [31%] is the leiomyoma on histopathology report similar to our study.

Study of GR et al.,2013⁷ showed among 698 cases the maximum number of women undergoing hysterectomy procedure was in 41-50 years of age group which is matching with our study.

Comparing all studies, almost all studies show the major age group of a women undergoing hysterectomy are belonging to 40-49 years of age, as is found in the present study. Major route of surgery is abdominal hysterectomy. Fibroid was the frequent indication for hysterectomy which was confirmed by histopathology.

CONCLUSION

REFERENCES

1. Jha R, Pant AD, Jha A, Adhikari RC, Sayami: Histopathological Analysis of Hysterectomy Specimens, J Nepal Med Assoc, vol.45, no.163, jul-sep,2006 pp. 283-290.
2. Shergill SK, Shergill HK, Gupta M, Kaur S: Clinicopathological study of hysterectomies, J Indian Med Assoc, vol.100, no.4, may,2002 pp.238-9.
3. Rather GR, Gupta Y, Bharadwaj S: Patterns of lesions in hysterectomy specimens, A prospective study, J.K. Science, vol.15, no.2, January,2013 pp.63-68.
4. Perveen S, Tayyab S. A clinicopathological review of elective abdominal hysterectomy. Journal of Surgery Pakistan (International). 2008 Jan;13(1):27.
5. Basanta Manjari Hota, B Kavitha, Clinicopathological Analysis of Hysterectomies in a Tertiary Care Hospital, INDIAN JOURNAL OF APPLIED RESEARCH : Volume-8 | Issue-7 | July-201.
6. Gangadharan V, Prasanthi C. Hysterectomy-a clinico-pathological correlation in a rural setting. Indian Journal of Basic and Applied Medical Research. 2016 Mar;5(2):8-15.
7. Rather GR, Gupta Y, Bardhwaj S. Patterns of lesions in hysterectomy specimens: a prospective study. JK science. 2013 Apr 1;15(2):63.
8. Ebinesh A, Sharada MS, Krishna MC. Clinicopathological correlation of abdominal hysterectomy specimens. International Journal of Science and Research (IJSR). 2013;4:1084-89.
9. Kaur SJ, Gupta RK, Kaur M. Clinicopathological Study of Uterine Lesions in Hysterectomy Specimens. Annals of International Medical and Dental Research. 2018;4(1):18.
10. Kaur M, Gupta RK, Kaur SJ, Kaur P. Clinicopathological study of leiomyomas in hysterectomy specimens. International Journal of Reproduction, Contraception, Obstetrics and Gynecology. 2018;7(4):1509-13.

Hysterectomy is the surgery done for many gynaecological diseases. The indications of this procedure show the high incidence of this condition in the locality. The indication of the disease decides the type of surgery performed.

Common age group of patients undergoing hysterectomy in the study was between 40-49 years. The most frequent presentation in patients in the hospital was abnormal uterine bleeding. The commonest indication for the surgery was found to be fibroid uterus. The common histopathological diagnosis was leiomyoma^{2,8}. Abdominal surgery was the major route of procedure.

The clinicopathological diagnosis was up to 97.06%. Hence it is concluded in this study that in every cases of hysterectomy, the specimen must be subjected to histopathology examination to confirm the indication of the disease. Histopathological analysis is essential and mandatory for the correct diagnosis and the management of the diseases⁹. Since the clinicopathological correlation is high [97.06%], it is confirmed that the histopathological analysis is important in finding and confirming the gynaecological disease. The clinicopathological correlation is the mandatory analysis to be made for optimal patient care and treatment¹⁰.