



Effect of curcumin on the antiepileptic drug, carbamazepine induced hepatotoxicity in albino rats

Ghassan F. Azhari^{1*}, Abdel-Baset M. Aref²

¹MOH, Makkah region, Saudi Arabia

²Zoology Department, Faculty of Science, South Vally University, Quena, Egypt

Received: 21-04-2015 / Revised: 28-05-2015 / Accepted: 30-05-2015

ABSTRACT

Carbamazepine (CZ) is a known antiepileptic drug. The present investigation studied the effect of curcumin on CZ-induced hepatotoxicity. Male albino rats were divided into 4 groups. Group I, served as a control. Group II, rats were orally administrated curcumin at a dose of 150 mg/kg body weight for 5 weeks. Group III, Animals were orally administrated with CZ at a dose level 50 mg/kg body weight, daily for 5 weeks. Group IV, rats were administrated CZ and curcumin daily for 5 weeks. CZ treatment showed a marked deterioration of liver structure where the hepatocytes were degenerated and appeared with cytoplasmic vacuolation and pyknotic nuclei. The blood vessels were congested, leucocytic infiltrations were observed. An increase in the levels of serum AST and ALT was recorded. Also a significant decrease in liver antioxidant enzymes, SOD and CAT, and increase in MDA was observed. These results indicated the oxidative damage as a result of CZ-induced liver injury. Treating animals with CZ and curcumin improved the histological structure of the live, increased SOD and CAT, and decreased lipid peroxidation

Key words: Carbamazepine, Liver, Curcumin, Histology, Antioxidant



INTRODUCTION

Plants are most ancient form of medicine. They are naturally rich in bioactive products with therapeutic values in several diseases. Curcumin, the yellow pigment isolated from the rhizome of turmeric (*Curcuma longa*), is widely used in folk medicine in the treatment of many diseases such as anthelmintic, asthma, gonorrhoea and urinary, and its essential oil is used in the treatment of carminative, stomachic and tonic [1]. Curcumin was found to have anti-inflammatory, immunomodulatory, antiatherogenic and antioxidant activity [2-6]. Treating rats with curcumin attenuated the arsenic, gentamicin, and acetaminophen-induced oxidative stress in rats [7-9]. Curcumin also prevented free radical formation-induced myocardial ischemia and paraquat-induced lung injury in rats [10]. Additionally, curcumin protected against diazinon-induced toxicity in blood, liver, and erythrocyte of male Wistar rats [11].

Carbamazepine (CZ), is an anticonvulsant used in the treatment of epilepsy, anorexia nervosa, panic

attack, anxiety disorder, posttraumatic stress disorder, migraine, and bipolar disorder, as well as other psychiatric conditions requiring the administration of mood stabilizers [12]. On the other hand, the drug has been linked to some side effects. Acute intoxication with this agent results in both neurologic and cardiovascular dysfunction. Neurologic manifestations may range from mild ataxia to profound coma with respiratory failure and are correlated with the plasma drug level [13]. The CN intoxication primarily influences the neurological system. Symptoms such as nystagmus, ataxia, dysarthria, latergia, dystonic reactions, seizures and respiratory depression can develop [14]. In prospective studies involving 1255 cases of exposure Matalon *et al.* [15] found that CBZ therapy increased the rate of congenital anomalies, mainly neural tube defects, cardiovascular and urinary tract anomalies, and cleft palate. Ponte [16] reported that administration of CZ induced thrombocytopenia, rash, and hepatic dysfunction. Forte *et al.* [17] reported a case of acute pancreatitis (AP) occurring in a patient under treatment with CZ. Hepatotoxicity is one of the adverse effects of CZ [18]. The present work was designed to study

*Corresponding Author Address: Ghassan F. Azhari, MOH, Makkah region, Saudi Arabia; E-mail: Azhari.ghassan@gmail.com

the effect of curcumin on Cz induced hepatotoxicity in albino rats.

MATERIALS AND METHODS

Healthy male Wistar albino rats, weighing 140-5 g were utilized. They were housed in groups of two per cage, maintained under controlled conditions of temperature ($22 \pm 2^\circ\text{C}$) and light (12 :12 L : D). Food and tap water were available ad libitum. All animals received human care according to the criteria outlined in the "Guide for the Care and Use of Laboratory Animals" prepared by the National Academy of Sciences and published by the National Institutes of Health. The animals were divided into four groups:

Group 1: Control group.

Group 2: Rats were orally administrated curcumin at a dose of 150 mg/kg body weight for 5 weeks. Dry turmeric rhizomes of the plant *Curcuma longa* were purchased from a local market and were crashed into powder, dissolved in distilled water and were orally given to the rats.

Group 3: Animals were orally administrated with carbamazepine (CZ) (Tegretol) at a dose level 50 mg/kg body weight, dissolved in mammalian saline daily for 5 weeks according to Santhrani *et al.* [18].

Group 4: Rats were administrated CZ and curcumin daily for 5 weeks.

Histological examination: The treated animals and their controls were anesthetized and dissected after 5 weeks of treatment. Livers were removed and fixed in 10% neutral formalin for 24 h, washed in running tap water for 12 h, and dehydrated in ascending grades of ethanol and two changes, cleared in two changes of xylene and embedded in paraffin wax and sections of 5 micrometer thickness were cut. Slides were stained with haematoxylin and eosin for histological examination.

Biochemical study: For biochemical study, sera were obtained by centrifugation of the blood samples and stored at 20°C until assayed for the biochemical parameters. Serum Aspartate aminotransferase (AST) and alanine aminotransferase (ALT) were measured colorimetrically using the method of Reitman and Frankel [19]. Malondialdehyde (MDA) levels were measured in the liver tissue homogenate of all experimental groups as a measure for lipid peroxidation according to Ohkawa *et al.*, [20]. Superoxide dismutase activity was measured using the methods of Rest and Spitznagel [21]. The principal of this method depends on the ability of

SOD to inhibit the power of phenazine methosulphate mediated to reduce the nitroblue tetrazolium. Catalase activity was determined from the rate of decomposition of H_2O_2 [22].

Statistical analysis: All statistical analyses were carried out using SPSS statistical software (SPSS for windows, version 11.0). All values were expressed as mean \pm standard deviation (SD). Differences between the groups were determined by one-way analysis of variance (ANOVA). Values were regarded as significantly different at $P < 0.05$.

RESULTS

Histological results: Histological examination of Liver of control rat showed normal architecture. The hepatic cells were found arranged in strands around the central vein and sinusoids appeared containing Kupffer cells (Fig. 1a). Animals administered curcumin showed normal structure and no histopathological alterations were observed. On the other hand, rats treated with CZ and examined after 3 weeks showed congested and enlarged central and portal veins (Fig.1b). Leucocytic infiltrations were observed in large areas of the liver (Fig.1c). Necrotic areas were abundant (Fig.1d). These histopathological changes were increased after 6 weeks of treatment. These specimens showed cytoplasmic vacuolization of the hepatocytes (Fig.2a) and fatty infiltrations (Fig.2b). Animals treated with CZ and curcumin showed an improvement in the structure of the liver. Sections of these specimens showed normal lobular arrangement of the hepatocytes. The hepatocytes appeared with normal nucleus and cytoplasm (Fig.2c).

Biochemical results: Non-significant difference in serum ALT activity was recorded in rats treated with curcumin in comparison with control group. Treating rats with CZ caused a significant increase in serum ALT activity 6 weeks of treatment. On the other hand, a significant decrease in ALT activity was recorded in animals treated with CZ and curcumin when compared with CZ group (Fig.3). Similarly, animals treated with CZ showed significant increase in serum AST activity while animals treated with CZ and curcumin showed a significant decrease in AST activity when compared with CZ treated group (Fig.3). Table 1 showed the effect of different treatments on Malondialdehyde (MDA) (index of tissue lipid peroxidation), superoxide dismutase (SOD) and catalase (CAT) in liver of animals examined after 6 weeks. Animals treated with CZ showed a significant increase in MDA level whereas the activity of SOD and CAT was found to be decreased. Treating rats with CZ and curcumin

decreased MDA level and increased SOD and CAT activity in comparison with CZ group.

DISCUSSION

The liver plays an important role in the maintenance, performance and regulating homeostasis of the body. It is involved with almost all the biochemical pathways to growth, fight against disease, nutrient supply, energy provision and reproduction. Due to its role in the transformation of environmental xenobiotics, the liver is at great risk of injury. Histological and biochemical results obtained in the present work revealed that CZ induced hepatotoxicity in rats. The histological changes include leucocytic infiltrations, necrosis and fatty infiltrations. Moreover, ALT and AST were increased significantly in sera of CZ-treated animals. These results are similar to those obtained by many investigators under the effect of CZ. Braide and Davies [23] reported that CZ elevates ALT in patients with epilepsy. Hopen *et al.*[24] recorded hepatotoxic reactions within 3-4 weeks after the initiation of CZ therapy and fatal hepatotoxicity occurs even early after intervention and discontinuation of the drug. Treating rats with CZ caused severe liver damage and increase ALT, AST and ALP, while albumin and total proteins decreased [18].

Antioxidant enzymes, mainly superoxide dismutase (SOD) and catalase (CAT), are the first line of defense against free radical induced oxidative stress; SOD is responsible for catalytic dismutation of highly reactive and potentially toxic superoxide radicals to hydrogen peroxide, and CAT is responsible for the catalytic decomposition of hydrogen peroxide to molecular oxygen and water. The obtained results showed that CZ caused elevation in MDA, the marker of lipid peroxidation and decreased the level of SOD and CAT. These results indicated that CZ induced oxidative stress in rats. Numerous studies reported that CBZ induces oxidative stress, possibly via the formation of free radicals and reactive oxygen species [25-27].

Concerning the effect of curcumin against CZ toxicity, the results showed that curcumin decreased the histopathological alterations and ALT and AST induced by CZ in the liver of rats. These results are in accordance with those reported by many investigators. Reyes-Gordillo *et al.* [28] reported that curcumin prevented cirrhosis induced by bile duct obstruction or CCl₄ in rats. Curcumin was found to modulate the increased activity of ALT and AST enzymes and plasma lipid levels in nicotine treated rats [29]. Zhang *et al.*[30] reported that curcumin have a protective effect against D-galactosamine induced liver injury in mice. Extracts of *Curcuma longa* showed hepatoprotective effect against CCl₄ [5], ethanol [31], thioacetamide [32] and lead acetate [33].

The present results showed that that curcumin decreased lipid peroxidation and improved the antioxidant status in liver of rats treated with CZ. Curcumin is the active constituent of *Curcuma longa*, which showed antioxidant activity. It scavenges and prevents formation of reactive oxygen species (ROS) [34] and reactive nitrogen species (RNS) [35]. In addition, curcumin was shown to induce several enzymatic anti-oxidants, such as glutathione transferase, catalase [36], and hemeoxygenase-1 (37). Canales-Aguirre *et al.*[38] reported that curcumin protects against the oxidative damage induced by the pesticide parathion in the hippocampus of the rat brain. Curcumin also showed a protective effect against diazinon-induced toxicity in blood, liver, and erythrocyte of male Wistar rats[11]. Otuechere *et al.*[39] showed that supplementation of curcumin attenuated the adverse effects of propanil hepatotoxicity by reducing lipid peroxidation levels and restored the levels of serum enzymes and reduced glutathione. It is concluded from the obtained results that curcumin can be used as a preventive agent against toxicity of antiepileptic drugs.

Table 1. Effect of different treatments on MDA, SOD and CAT in liver of rats

Treatment	MDA($\mu\text{mol/ml}$)	SOD($\mu\text{g/ml}$)	CAT($\mu\text{g/ml}$)
Control	58.6 \pm 2.2	43.5 \pm 2.2	61.2 \pm 1.2
Curcumin	56.4 \pm 3.5	44.4 \pm 1.1	59.4 \pm 2.2
CZ	79.5 \pm 3.2*	30.5 \pm 2.3*	39.5 \pm 1.4*
CZ+ curcumin	60.3 \pm 1.2	39.4 \pm 1.2	52.7 \pm 2.2

(*). Significant at P<0.05 compared with control group.

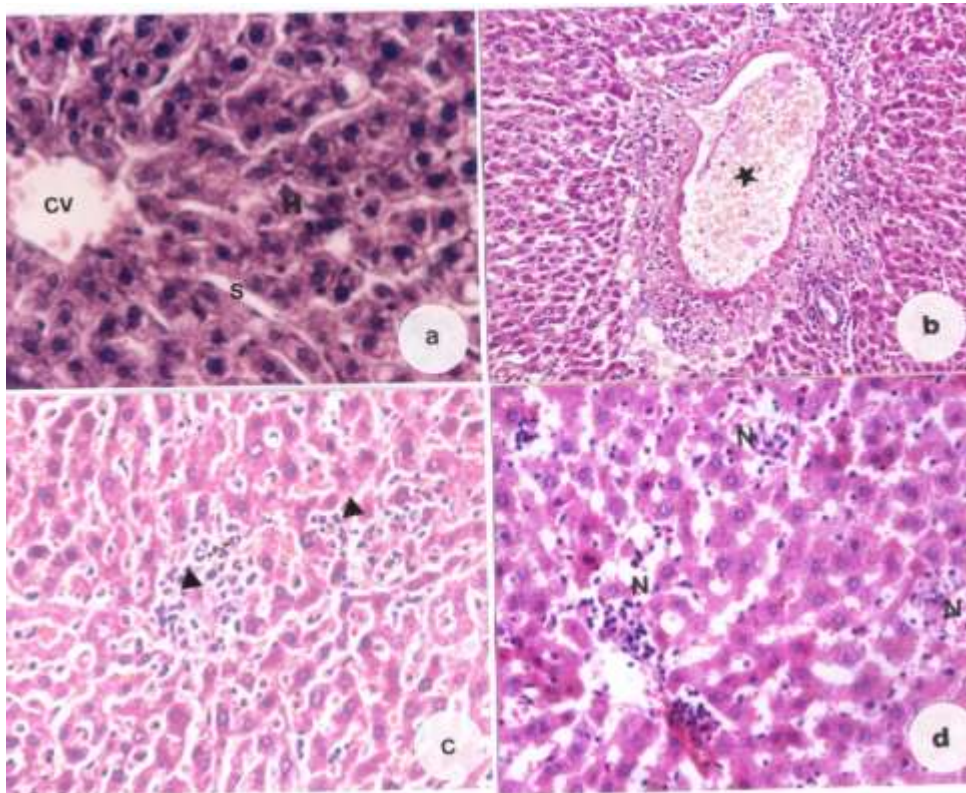


Fig. 1. a). Section in liver of a control rat showing central vein (CV), hepatocytes (H) and blood sinusoid (S).
b). CZ treated rat after 3 weeks showing congested and dilated portal vein(*)
c). CZ treated rat after 3 weeks showing leucocytes infiltrations in the sinusoids (arrow head)
d). CZ treated rat after 3 weeks showing necrotic areas (N), (H&E X400).

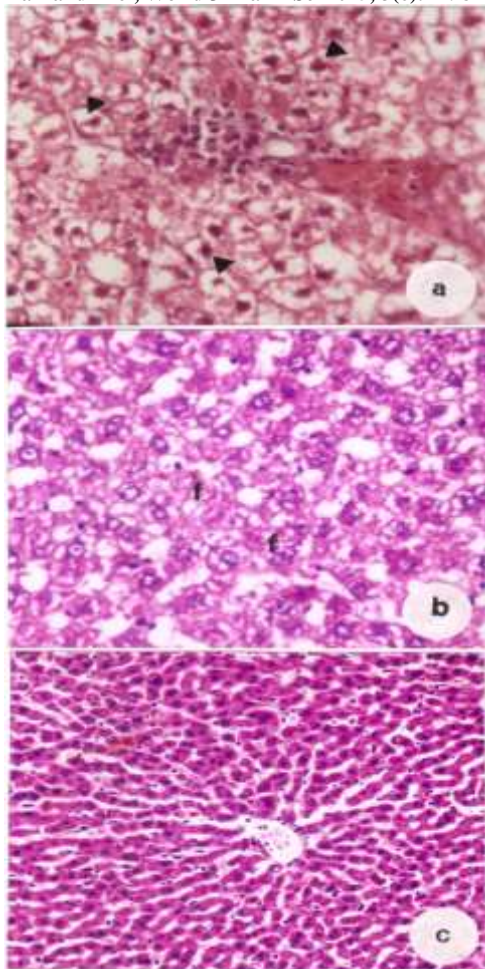


Fig.2. a). CZ treated rat after 6 weeks showing cytoplasmic vacuolation of the hepatocytes (arrow heads), (H&E X400); b). CZ treated rat after 6 weeks showing fatty infiltrations (f), (H&E X400); c).CZ+curcumin showing normal appearance of hepatocytes, (H&E X200).

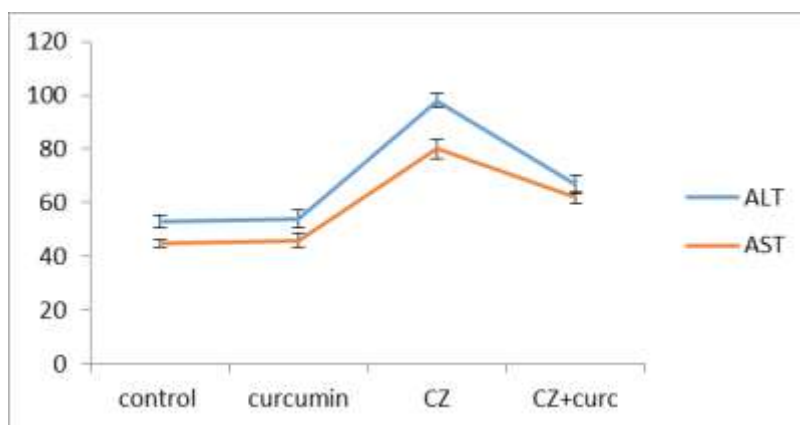


Fig.3. Effect of different treatment on serum ALT and AST.

References

- [1]. Devasagayam TP, Tilak JC, Boloor KK, Sane KS, Ghaskadbi SS, Lele RD.(2004). Free radicals and antioxidants in human health: current status and future prospects. *J Assoc Physicians India* 52:794-804.
- [2].Kim KJ, Yu HH, Cha JD, Seo SJ, Choi NY, You YO (2005). Antibacterial activity of *Curcuma longa* L. against methicillin-resistant *Staphylococcus aureus*. *Phytother Res* 2005, 19(7):599–604.
- [3].Kohli K, Ali J, Ansari M, Raheman Z (2005). Curcumin: a natural anti-inflammatory agent. *Indian J Pharmacol* 37(3):141–147.

- [4]. Miriyala S, Panchatcharam M, Rengarajulu P (2007). Cardioprotective effects of curcumin. In: The molecular targets and therapeutic uses of curcumin in health and disease 595:359–377.
- [5]. Maizura M, Aminah A, Wan Aida W (2011). Total phenolic content and antioxidant activity of kesum (*Polygonum minus*), ginger (*Zingibe officinale*) and turmeric (*Curcuma longa*) extract. *Int Food Res J* 18:526–531.
- [6]. Sengupta M, Sharma GD, Chakraborty B (2011). Hepatoprotective and immunomodulatory properties of Aqueous extract of *Curcuma longa* in carbon tetrachloride intoxicated Swiss albino mice. *Asian Pac J Trop Biomed*, 1(3):193–199.
- [7]. Farombi E.O., Ekor, M. (2006). Curcumin attenuates gentamicin-induced renal oxidative damage in rats. *Food and Chemical Toxicology*, 44(9): 1443–1448.
- [8]. Cekmen, M. Ilbey, Y., Ozbek, E., Simsek, A. Somay, A., Ersoz, C. (2009). Curcumin prevents oxidative renal damage induced by acetaminophen in rats. *Food and Chemical Toxicology*, 47(7): 1480–1484.
- [9]. El-Demerdash, F.M., Yousef, M.I., Radwan, F.M. (2009). Ameliorating effect of curcumin on sodium arsenite-induced oxidative damage and lipid peroxidation in different rat organs. *Food and Chemical Toxicology*, 47(1): 249–254.
- [10]. Venkatesan, N. (2000). Pulmonary protective effects of curcumin against paraquat toxicity. *Life Sciences*, 66(2): 21–28.
- [11]. Messarah, M. Amamra, W. Boumendjel, A. (2013). Ameliorating effects of curcumin and vitamin E on diazinon-induced oxidative damage in rat liver and erythrocytes. *Toxicology and Industrial Health* 29(1): 77–88.
- [12]. Bernus I, Dickinson RG, Hooper WD, Eadie MJ. (1996). Dose-dependent metabolism of carbamazepin in humans. *Epilepsy Res* 24:163-72.
- [13]. May DC (1984). Acute carbamazepine intoxication: clinical spectrum and management. *South Med J*. 77(1):24-6.
- [14]. Perez A., Wiley JF. (2005). Pediatric Carbamazepine Suspension Overdose-Clinical Manifestations and Toxicokinetics. *Ped Emerg Care* 21:252-4.
- [15]. Matalon S, Schechtman S, Goldzweig G, Ornoy A. (2002). The teratogenic effect of carbamazepine: a meta-analysis of 1255 exposures. *Reprod Toxicol*. 16(1):9-17.
- [16]. Ponte CD (1983). Carbamazepine-induced thrombocytopenia, rash, and hepatic dysfunction." *Drug Intell Clin Pharm* 17 : 642-4
- [17]. Forte A, Gallinaro L, Montesano G, Turano R, Bertagni A, Illuminati G. (1996). A possible case of carbamazepine induced pancreatitis. *Riv Eur Sci Med Farmacol*. 18(5-6):187-9.
- [18]. Santhrani, T., Maheswari, E., Saraswathy, G. (2013). Carbamazepine provoked hepatotoxicity: attenuation by vitamin C. *Oxid Antioxid Med Sci* 2(1):37-43.
- [19]. Reitman S. and Frankel, S. (1975). Colorimetric Determination of Glutamic Oxaloacetic and Glutamic Pyruvate Transaminase, *J. Clinical Pathology*, 1975, : 28-56.
- [20]. Ohkawa H, Ohishi N, Yagi K. (1979). Assay for lipid peroxides in animal tissues by thiobarbituric acid reaction. *Anal. Biochem*, 95: 351-358.
- [21]. 24. Rest R.F, Spitznagel, J.K. (1977): Subcellular distribution of superoxide dismutases in human neutrophils. Influence of myeloperoxidase measurement of superoxide dismutase activity. *Biochem. J*, 166(2):145-153.
- [22]. Aebi H, Wyss SR, Scherz, B, Skvaril, F. (1974): Heterogeneity of erythrocyte catalase II. Isolation and characterization of normal and variant erythrocyte catalase and their subunits. *Eur. J. Biochem*, 48(1): 137-145.
- [23]. Braide SA, Davies TJ. (1987) Factors that affect the induction of gamma glutamyltransferase in epileptic patients receiving anti-convulsant drugs. *Ann Clin Biochem*, 24:3919.
- [24]. Hopen G, Nesthus I, Laerum OD. (1981). Fatal carbamazepin associated hepatitis. Report of two cases. *Acta Med Scand* 210:333-5.
- [25]. Madden S, Maggs JL, Park BK. (1996). Bioactivation of carbamazepin in the rat in vivo. Evidence for the formation of reactive arene oxide(s). *Drug Metab Dispos*, 24:469-79.
- [26]. Li ZH, Li P, Randak T. (2010). Effect of a human pharmaceutical carbamazepin on antioxidant responses in brain of a model teleost in vitro: an efficient approach to biomonitoring, *J Appl Toxicol* 30:644-649
- [27]. Aycicek A, Iscan A. (2007). The effects of carbamazepin, valproic acid and phenobarbital on the oxidative and antioxidative balance in epileptic children. *Eur Neurol*, 57:65-9
- [28]. Reyes-Gordillo K, Segovia J, Shibayama M, Tsutsumi V, Vergara P, Moreno MG, (2008). Curcumin prevents and reverses cirrhosis induced by bile duct obstruction or CCl4 in rats: role of TGF- β modulation and oxidative stress. *Fundam Clin Pharmacol*, 22:417-27.
- [29]. Kalpana, C., Rajasekharan, K.N., Menon, V.P (2005). Modulatory effects of curcumin and curcumin analog on circulatory lipid profiles during nicotine-induced toxicity in Wistar rats. *J. Medicinal Food*, 8(2): 246–250.
- [30]. Zhang J, Xu L, Zhang L, Ying Z, Su W, Wang T. (2014). Curcumin attenuates D-galactosamine/lipopolysaccharide-induced liver injury and mitochondrial dysfunction in mice. *J Nutr.*, 144(8):1211-8.
- [31]. Singh, I., Vetrivelan, S., Shankar, J., Gayathiri, S., Hemah, C., Shereenjeet, G, Yaashini, G. (2012). Hepatoprotective activity of aqueous extract of *Curcuma longa* in ethanol induced hepatotoxicity in albino wistar rats. *Int J Phytopharmacology*, 3(3): 226-233.
- [32]. Salama SM, Abdulla MA, AlRashdi, AS, Ismail S, Alkiyumi, S, Golbabapour, S (2013). Hepatoprotective effect of ethanolic extract of *Curcuma longa* on thioacetamide induced liver cirrhosis in rats. *BMC complementary and Alternative medicine*. 13:1-17
- [33]. Baxla SL, Gora RH, Kerketta P, Kumar N, Roy BK and Patra PH (2013). Hepatoprotective effect of *Curcuma longa* against lead induced toxicity in Wistar rats. *Vet World* 6(9): 664-667
- [34]. Betancor-Fernandez A, Perez-Galvez A, Sies H, Stahl W. (2003). Screening pharmaceutical preparation containing extracts or turmeric rhizome, artichoke leaf, devil's claw root and garlic or salmon oil for antioxidant capacity. *J. Pharm. Pharmacol.* 55: 981-986.
- [35]. Kim JE, Kim AR, Chung HY, Han SY, Kim BS, Choi JS. (2003). *In vitro* peroxynitrite scavenging activity of diarylheptanoids from *Curcuma longa*. *Phytother. Res.* 17: 481-484.
- [36]. Iqbal M, Sharma SD, Okazaki Y, Fujisawa M, Okada S. (2003). Dietary supplement of *Curcuma* enhances antioxidant and phase II metabolizing enzymes in ddY male mice: Possible role in protection against chemical carcinogenesis and toxicity. *Pharmacol. Toxicol.* 92 : 33-38.
- [37]. Motterlini R, Foresti R, Bassi R, Green CJ. (2000). Curcumin, an antioxidant and anti-inflammatory agent, induces heme oxygenase-1 and protects endothelial cells against oxidative stress. *Free Radic. Biol. Med.* 28: 1303-1312.
- [38]. Canales-Aguirre, A.A., Gomez-Pinedo, U.A., Luquin, S., Ramirez-Herrera, M.A., Mendoza-Magana, M.L., Feria-Velasco, A. (2012): Curcumin protects against the oxidative damage induced by the pesticide parathion in the hippocampus of the rat brain. *Nutritional Neuroscience*, 15(2): 62–69.
- [39]. Otuochere, C.A., Sunny O. Abarikwu, S.O., Olateju, V., I., Azeezat L. Animashaun, A.L., Kale, O.E. (2014). Protective Effect of Curcumin against the Liver Toxicity Caused by Propanil in Rats. *International Scholarly Research Notices*, 2014, doi.org/10.1155/2014/853697