



A retrospective study of crossed fused pelvic kidney

K. Parthiban¹, Vino Victor Jesudas^{2*}, Nandhini Devi S³

¹Associate Professor of Anatomy, ²Director and Professor, ³Postgraduate of Anatomy, Institute of Anatomy, Madurai Medical College, Madurai, Tamil Nadu, India

Received: 01-02-2019 / Revised Accepted: 25-02-2019 / Published: 28-02-2019

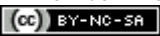
ABSTRACT

Crossed fused ectopic kidney is an unusual congenial malformation of the urinary tract in which both kidneys are located on one side of the midline and are fused together. Usually this condition is identified in the autopsy specimen rather than in general clinical scenario. Workup was done in primigravida antenatal mother's along with regular ultrasound screening during pregnancy to detect any abnormality in antenatal mother and prevent complication. The aim of the workup is to screen asymptomatic antenatal mothers and aid them for a healthy outcome of pregnancy. Study was also conducted in 20 cadavers. A 19 years old primigravida diagnosed with crossed fused pelvic kidney. [left side] which is a rare anomaly lead to retrospective study of this condition.

Key Word: Crossed Fused Ectopic kidney, Cake Kidney, Primigravida, CADAVERS

Address for Correspondence: Dr. Vino Victor Jesudas, Director and Professor, Institute of Anatomy, Madurai Medical College, Madurai, TamilNadu, India-625020; E-mail: vinovictor@rocketmail.com

How to Cite this Article: K. Parthiban M, Vino Victor Jesudas, Nandhini Devi S. A retrospective study of crossed fused pelvic kidney. World J Pharm Sci 2019; 7(3): 152-155.

This is an open access article distributed under the terms of the Creative Commons Attribution-NonCommercial-ShareAlike 4.0 International License, which allows adapt, share and build upon the work non-commercially, as long as the author is credited and the new creations are licensed under the identical terms. 

© 2019 World J Pharm Sci

INTRODUCTION

Cake kidney or fused pelvic kidney is a very rare congenital anomaly with a very few cases described in the literature [8,9,10]. The term is used to describe completely fused renal mass located in the pelvic cavity and drained generally by two ureters which do not cross the midline. Cake kidney accounts for only about 2% of all fused kidney types. The estimated incidence is 1/65000 to 1/375000 cases.

The most common pathologic condition associated with cake kidney is vaginal agenesis, bicornuate or unicornuate uterus, sacral agenesis, caudal regression syndrome, tetralogy of fallot and spina bifida [11,12,13]. Generally patient remain asymptomatic, more common in males [7] with male to female ratio of about 2-3:1. Developmentally, when the renal anlagen fail to ascend and remain in the pelvic cavity extensively fusing with each other. A cake kidney is formed retaining the primitive vascular supply. Vascular supply may be derived from single renal artery and single renal vein. The single renal vascular supply to Cake kidney increases the risk of damage by pelvic trauma, pregnancy or space occupying lesion. This abnormality is usually detected incidentally at autopsy, surgery and radiological investigations. If diagnosed as fused kidney then investigations should be done to rule out other

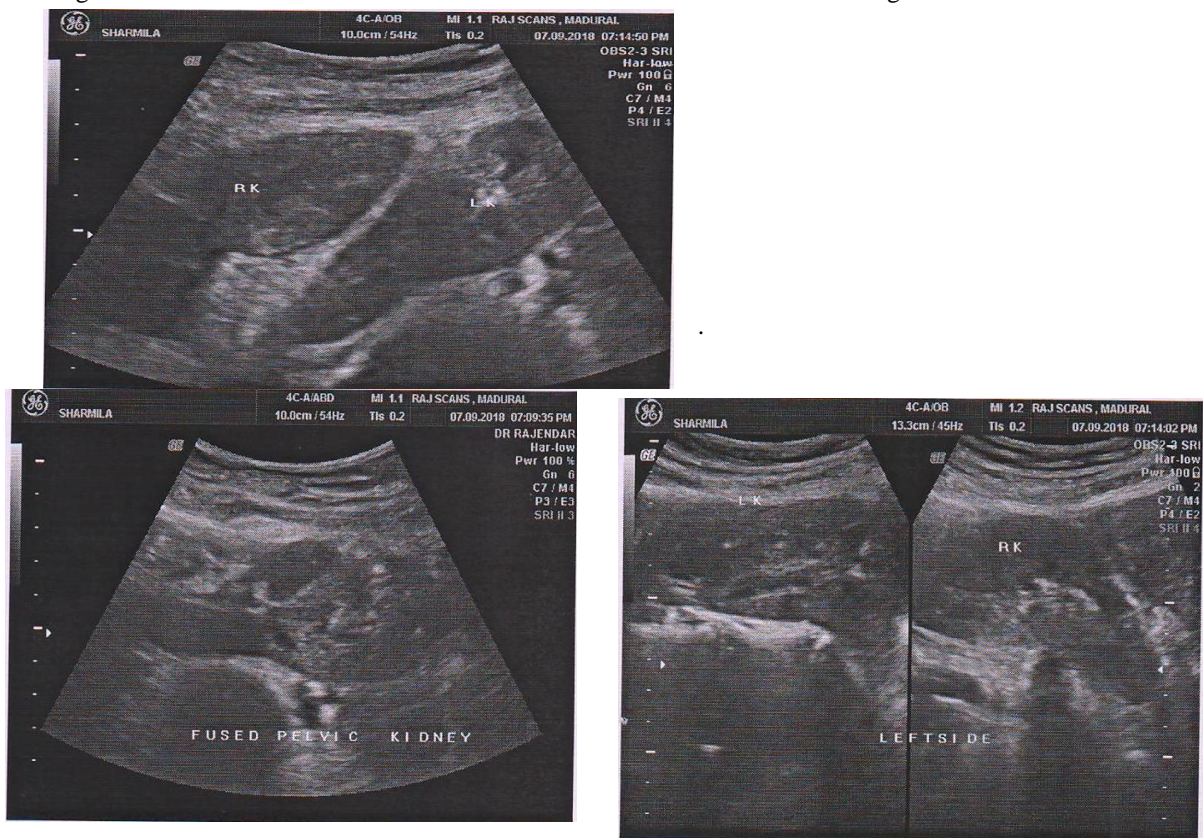
abnormalities. Active intervention is not always needed and patient usually will be asymptomatic.

MATERIALS AND METHODS

The study was conducted in Institute of Anatomy, Madurai Medical College in 20 cadavers and Department of radiology, Government Rajaji Hospital, Madurai Medical College where 60 antenatal cases were screened during the period of June 2018 to Dec 2018. Screening was done in asymptomatic, primigravida with no other co-morbidities with regular antenatal screening. Maternal abdomen was also screened to rule out any congenital abnormalities in the mother and to prevent associated complication in pregnancy and for safe delivery. The finding was appropriately documented and ultrasound pictures were taken with consent of the patient. Cadaveric study was also done in this period.

OBSERVATION

A 19 years old primigravida with history of 7 months of amenorrhea, came for routine antenatal ultrasound screening with no other specific complaint. With consent maternal abdomen screened both kidneys were seen in the left side of the pelvis in vertical position and fused together - crossed fused pelvic kidney. Both kidneys were normal in size with regular cortical outline.

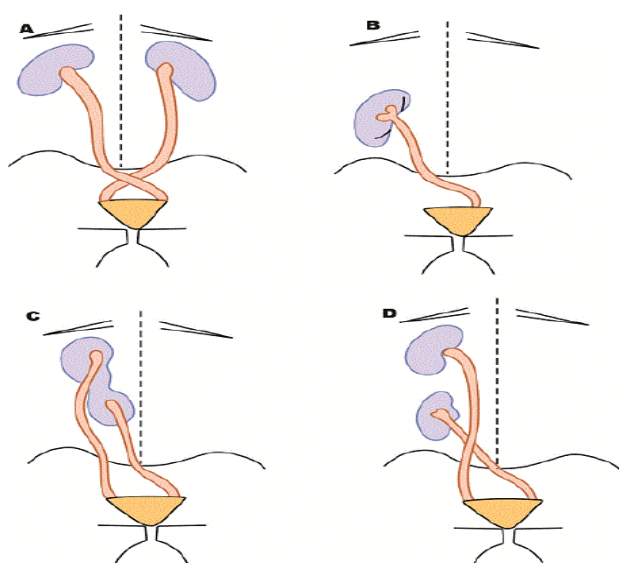


Right Kidney measures – 92*41mm in size.
Left Kidney measures – 97*40mm in size.

Cortical thickness and echoes are normal in both kidneys. No evidence of medical renal disease. No evidence of calculi / hydronephrosis in both kidneys. Both ureters were not dilated. No evidence of focal renal mass lesion/pyelonephritic focus. No Bladder pathology made out. Both kidneys lying at the right paravertebral region at L₄ – L₅ that is at the same level. Superior, mid region and inferior pole were fused. On retrospective study in 60 antenatal mothers and 20 cadavers the anomaly could not be made out which proves it to be the rarest anomaly.

DISCUSSION

CFRE results from over bending and rotation of the caudal end of the developing embryo leading to the inability of the ureteric bud to communicate with the more distant ipsilateral metanephros. The



CFEK is sporadically reported in the literature because this anomaly may remain as a silent clinical entity without producing any signs and symptoms. Sharma V, reported two cases of L-shaped kidney in females and one case of inferior ectopia in a male (2). Tur K vatan at al reported four cases, of which two were inferior ectopia (both females) and two L-shaped tandem kidneys (both males) and hydronephrosis was noted in two cases (3). Yin et al described a right to left CFREK of superior ectopia type in male patient with thoracic scoliosis. (4). Sigmoid type of kidney which is second common type of CFREK associated with stayhorn calculus was also reported. (5)

Solanki et al evaluated 5 boys and 1 girl, all having CFREK and noted left to right ectopia in 4 cases and right to left cross over in 2 cases. (6)

kidney is then attracted to the closer contralateral side.

MC Donald and Mc Clellan classified crossed fused renal ectopia into six types (1). (A) Unilateral fused kidney inferior ectopia with the upper pole of the crossed ectopic kidney fusing with the lower pole of the orthotopic ipsilateral mate. (B) Sigmoid or S-shaped kidney in which the crossed kidney lies inferiorly with the renal pelvis directed laterally. (C) Unilateral Lump kidney with fusion occurring over a wide margin and both renal pelvis directed anteriorly; located more inferiorly. (D) L-Shaped or Tandem kidney in which the crossed kidney lies inferiorly and transversely fusing with the lower pole of the normal kidney. (E) Unilateral disc kidney fusion occurs along the medial border. (F) Unilateral fused kidney superior ectopia type is the least common type the ectopic kidney is placed superiorly with its lower pole fusing with the upper pole of the normal kidney.

Kaufman and find later reported a cake or lump kidney with left to right ectopia located in the right lumbar region in 81 years old female cadaver. (4) Crossed fuse renal ectopia is one of the rare congenital abnormalities. The prevalence of the crossed renal ectopia with fusion was estimated to the 1 in 1000 live births. The incidence of autopsy can vary from 1 in 2000 to 1 in 7500 (2,3).

CFREK are generally located in abdomen at a lower level or in pelvic cavity. Crossed fusion variety is most common and present in 90% of cases. Many Theory like influence of genetic factor, teratogenic factor or malignant and abnormal rotation of caudal end of embryo that will lead to aberrant development of metanephric blastema and ureteric during the 4th to 8th week of gestation. Hence both kidneys could not achieve normal position. But the

cause of crossed ectopia is still not known and the shape and site of crossed kidneys depend upon the time and amount of fusion and extent of rotation. Mostly patients are asymptomatic. If symptomatic then the most common presenting symptoms are abdominal or flank pain, a palpable mass, dysuria or hematuria. Ureteral orifices are usually orthotopic. Only 3% have ectopia ureteric orifices. Vesicoureteric reflux (VUR) ureteropelvic junction (UPJ) obstruction, ureterocele, nephrolithiasis and very rarely carcinoma are the common associated anomaly that can lead to pyelonephritis. Investigation like USG, CECT, MRI, IVP, MDCT, UROGRAPHY are the investigation of choice. Rarely temporary episodes of urinary pathway obstruction can lead to acute abdominal pain. Our patient had no complaints, finding was only accidental. Only regular follow up

needed. If symptomatic patients can be easily managed only by conservative measures. Our patient delivered an alive preterm male baby by Cesarean section [obstetric indication] and neonatal screening of baby abdomen by ultrasound had no abnormalities.

CONCLUSION

Mostly detected incidentally commonly detected in autopsy specimen. The cadaveric study done also proves that this is a rare anomaly. This can be observed in various clinical forms and management should be planned according to the clinical presentation and anatomical abnormality because most of the patients remain asymptomatic throughout their life.

REFERENCES

1. MC Donald JH, MC Clellan DS (1957) Crossed renal ectopia. *Am J surg* 93:995-1002.
2. Sharma V, Ramesh Babu CS, Gupta OP. (2015) Horseshoe kidney: A multidetector computed tomography study. *Int J Anat Res.* 3:1049-1055.
3. Turkvatan A, Olcer T, Cumbur T (2009) Multidetector CT urography of renal fusion anomalies. *Diagn Interv Radiol* 15:127-134.
4. Yin Z, Yang JR, Wei YB, Zhou KQ, Yan B (2014) A new subtype of crossed fused ectopia of the kidneys. *Urology* 84: e27.
5. Patel TV, Singh AK (2008) Crossed fused ectopia of the kidneys. *Kidney Int* 73:662.
6. Solanki S, Bhatnagar V, Gupta AK, Kumar R (2013) Crossed fused renal ectopia: Challenges in diagnosis and management *J Indian Assoc Pediatr Surg* 18:7-10.
7. Kaufman MH, Findlater GS (2001) An unusual case of complete renal fusion giving rise to a 'cake' or 'lump' kidney. *J Anat* 198: 501-504.
8. Turkvatan A, Olcer T, Cumhuri T. Multidetector CT Urography of renal fusion anomalies. *Diagn Interv Radiol.* 2009; 15:127-34 [PubMed]
9. Calado AA, Macedo A Jr. Srougi M (2004) Cake kidney drained by single ureter, *Int Braz J Urol* 30:321-322.
10. Turkvatan A, Demir D, Olcer T, Cumhuri T (2006) Cake kidney: MDCT urography for diagnosis. *Clin Imaging* 30: 420 - 422.
11. Goren E, Eidelman A (1987) Pelvic cake kidney drained by single ureter. *Urology* 30: 492-493.
12. Rosenkrantz AB, Kopec M, Laks S (2010) Pelvic cake kidney drained by a single ureter associated with unicornuate uterus. *Urology* 76:53-54.
13. Schwartz MJ, Bartolotta R, Brill PW, Kovanlikaya A, Hanna M (2010) Pelvic cake kidney with a solitary ureter and bilateral congenital absence of the vas deferens. *Urology* 75:170-172.
14. Shapiro E, Telegrafis S. In Campbell-Walsh Urology Book, Wein A. J. et al, editors. 11th ed. Philadelphia: WB Saunders; 2016. Anomalies of form and fusion, crossed renal ectopia with and without fusion; pp.2988-93.
15. Boyan N, Kubat H, Uzum A. Crossed renal ectopia with fusion: report of two patients *Clinical Anatomy.* 2007; 20(6):699-702.
16. Abshouse B S, Bhisitkul I. Crossed renal ectopia with and without fusion. *Urol. Int.* 1959;9:63.
17. Patel T V, Singh A K. Crossed fused ectopia of the kidneys. *Kidney International.* 2008;73(5):662.
18. Akdogan L, Oguz A K, Ergun T, Ergun I. The rarest of the rare: crossed fused renal ectopia of the superior ectopia type. *Case reports in Nephrology.* 2015 Article ID 742419, 4 pages, 2015.
19. Solanki S, Bhatnagar V, Gupta A K, Kumar R. Crossed fused renal ectopia: Challenges in diagnosis and management. *Journal of Indian Association of Pediatric Surgeons.* 2013;18(1):07-10.
20. Sharma V, Ramesh Babu CS, Gupta OP. Crossed fused renal ectopia: Multidetector computed tomography study. *Int J Anat Res.* 2014;2(2):305-09.
21. Ramaema D P, Moloantoa W, Parag Y. Crossed renal ectopia without fusion-An unusual cause of acute abdominal pain : A case report. *Case Reports in Urology.* Vol.2012, Article ID 728531, 4 pages, 2012.