



---

## Review on Pott's Disease

Priya Joy<sup>1</sup>, Jesly Susan Thomas<sup>1</sup>, Renuka R<sup>2</sup>, Elesy Abraham<sup>3</sup>

<sup>1</sup>Third Year Pharm D Student, <sup>2</sup>Assistant Professor and <sup>3</sup>Principal, Nazareth College of Pharmacy, Othara P. O, Thiruvalla, Kerala, India

*Received: 02-01-2018 / Revised Accepted: 25-01-2018 / Published: 01-02-2018*

---

### ABSTRACT

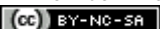
Pott's disease (PD) otherwise known as spinal tuberculosis is an extra-pulmonary tuberculosis that affects the spine. It is a combination of osteomyelitis and arthritis which involves multiple vertebrae. This accounts for less than 1% of total tuberculosis (TB) cases, but it accounts for approximately half of all cases of musculoskeletal tuberculosis. Spinal tuberculosis is more common in children and young adults. The disease is named after Percivall Pott (1714–1788), a British surgeon. The lower thoracic and upper lumbar vertebrae are the areas of the spine most often affected. The formal name for the disease is tuberculous spondylitis. The incidence of spinal tuberculosis is increasing in developed nations because of immigration. PD is an important differential diagnosis of malignancy that should be diagnosed instantly. Tuberculous involvement of the spine has the potential to cause serious morbidity, including permanent neurologic deficits due to compression of adjacent neural structures and severe spinal deformities. A possible effect of this disease is vertebral collapse. Therefore, early diagnosis and management of spinal TB has special importance in preventing these serious complications. Immunocompromised state and multidrug resistance to standard drugs (8 to 10 %) are the current (and future) challenges to spinal tuberculosis therapy.

**Keywords:** Tuberculosis; Pott's disease; Tuberculosis of spine; back pain

---

**Address for Correspondence:** Mrs Renuka R, Assistant Professor, Department of Pharmacy Practice, Nazareth College of Pharmacy, Othara P.O, Thiruvalla, Kerala, India;  
E-mail: [renuka.karthika@gmail.com](mailto:renuka.karthika@gmail.com)

**How to Cite this Article:** Priya Joy, Jesly Susan Thomas, Renuka R, Elesy Abraham. Review on Pott's Disease. World J Pharm Sci 2018; 6(2): 84-90.

This is an open access article distributed under the terms of the Creative Commons Attribution-NonCommercial-ShareAlike 4.0 International License, which allows adapt, share and build upon the work non-commercially, as long as the author is credited and the new creations are licensed under the identical terms. 

## INTRODUCTION

Pott's disease is a presentation of extrapulmonary tuberculosis that affects the spine, a kind of tuberculous arthritis of the intervertebral joints. The lower thoracic and upper lumbar vertebrae are the areas of the spine most often affected. The typical site of involvement is the anterior aspect of the vertebral body adjacent to the subchondral plate and occurs most frequently in the lower thoracic vertebrae. The effect of this disease is vertebral collapse and when this occurs anteriorly, anterior wedging results, leading to kyphotic deformity of the spine. Other possible effects can include compression fractures, spinal deformities and neurological insults, including paraplegia.

Back pain is the earliest and most common symptom. Patients with Pott's disease usually experience back pain for weeks before seeking treatment and the pain caused by spinal TB can present as spinal or radicular. Although both the thoracic and lumbar spinal segments are nearly equally affected, the thoracic spine is frequently reported as the most common site of involvement. Together, thoracic and lumbar involvement comprise of 80-90% of spinal TB sites.

Scientifically, it is called tuberculous spondylitis and it is most commonly localized in the thoracic portion of the spine.

Pott's disease, also called tuberculosis of the spine, disease caused by infection of the spinal column or vertebral column mainly by the tuberculosis bacillus, *Mycobacterium tuberculosis*. Pott disease is characterized by softening and collapse of the vertebrae, resulting in a hunchback curvature of the spine. The condition is named after an English surgeon, Sir Percivall Pott, who described it in a monograph published in 1779. The infection begins in the vertebra and spreads slowly to contiguous structures. Abscesses may form and drain into soft tissues adjacent to the spine, causing pain in sites distant from the infection. As a result the spinal nerves are affected, and paralysis may result. The course of the disease is slow, lasting months or years. Treatment includes chemotherapy against the *M. tuberculosis* bacillus and orthopedic care of the spinal column. Modern treatment has made Pott's disease rare in developed countries, but in less-developed countries it still accounts for up to 2 percent of all tuberculosis cases and particularly affects children [1,2,3].

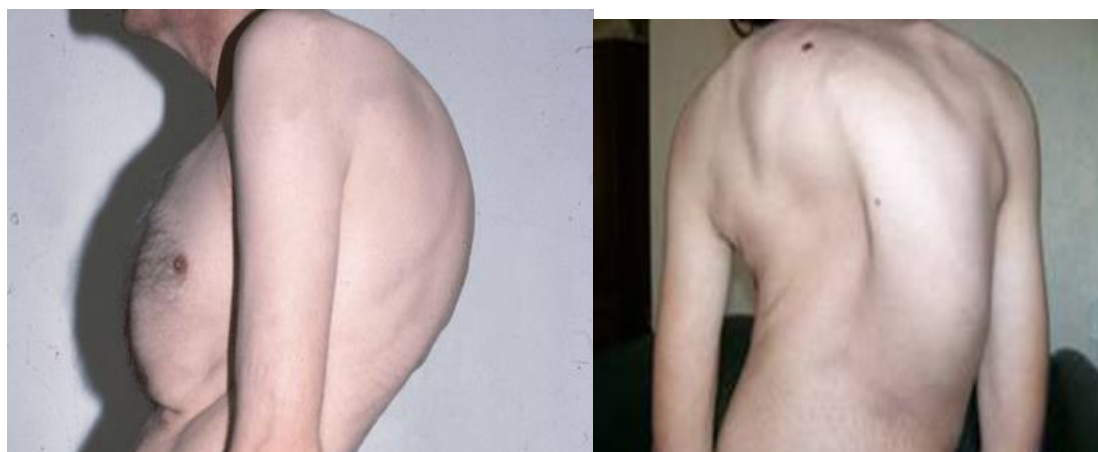

Figure 1: Spinal TB affected patients

## EPIDEMIOLOGY

In 2005, there were 8.8 million new tuberculosis (TB) patients all over the world. Of these, 7.4 million were in Asia and sub-Saharan Africa. Involvement of the spine reportedly occurs in less than 1-2% of patients who contract TB. Although the incidence of tuberculosis increased in the late 1980's to early 1990's, the total number of cases has decreased in recent year. Bone and soft-tissue tuberculosis accounts for approximately 10% of extrapulmonary tuberculosis cases and between 1% and 2% of total cases. Tuberculosis spondylitis is the most common manifestation of musculoskeletal

tuberculosis, accounting for approximately 40-50% of cases. Approximately 1-2% of total tuberculosis cases are attributable to Pott's disease [1,2,5].

## ETIOLOGY

The organism causing Pott's disease is *mycobacterium tuberculosis*. The primary mode of transmission the bacteria travels to the spine is hematogenously from an extraspinal site of infection. It is common to travel from the lungs in adults but the primary site of infection is often unknown in children. The infection also spread through the lymphatic system. Once being spread,

the infection can target vertebrae, intervertebral discs, the epidural or intradural space within the spinal canal and adjacent soft tissue. When the infection is developing, it can spread up and down the vertebral column, stripping the anterior and posterior longitudinal ligaments and the periosteum from the front and sides of the vertebral bodies. This results in loss of the periosteal blood supply and distraction of the anterolateral surface of the vertebrae.

If a single vertebra is affected, the surrounding intervertebral discs will remain normal. If two adjacent vertebrae are affected, the intervertebral disc between them will also collapse and become avascular. Due to the vascularity of intervertebral discs in children, the discs can become a primary site of infection rather than spreading from the vertebrae.

Spinal cord compression in Pott's disease is usually caused by paravertebral abscesses which can also develop calcifications or sequestra within them. An old abscess can also form, If the infection reaches adjacent ligaments and soft tissues. Other causes of neurological involvement include dural invasion from granulation tissue, sequestered bone, intervertebral disc collapse or a dislocated vertebra. As a result of stretching of the spinal cord within the vertebral foramen of the deformed spine neurological symptoms can occur at any point.[1,2,6,7].

#### CHARACTERISTICS/CLINICAL PRESENTATION

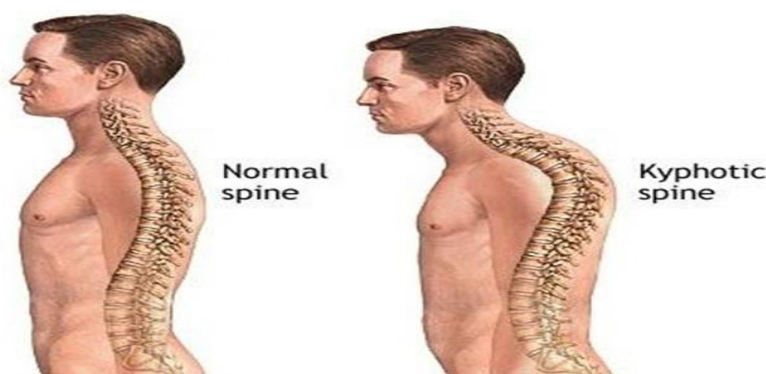


Figure 2: Kyphotic spine

#### ASSOCIATED CO-MORBIDITIES

- Immunosuppressive Disorders
- HIV/AIDS
- TB
- Gastrectomy
- Peptic Ulcer
- Drug Addiction
- Alcoholism

#### Spinal Involvement

Lower thoracic vertebrae is the most common area of involvement (40-50%), followed by the Lumbar spine (35-45%). Approximately 10% of Pott's disease cases involve the cervical spine. The thoracic spine is involved in about 65% of cases, and the lumbar, cervical and thoracolumbar spine in about 20%, 10% and 5%, respectively. The atlanto-axial region may also be involved in less than 1% of cases.

#### Physical Findings

- Localized Tenderness
- Muscle Spasms
- Restricted Spinal Motion
- Spinal Deformity
- Neurological Deficits
- Back Pain

#### Neurological Signs

Neurologic abnormalities occur in 50% of cases and can include spinal cord compression with the following:

- Paraplegia
- Paresis
- Impaired sensation
- Nerve root pain. [1,2,3,4,6].

#### LATE COMPLICATIONS

- Abscesses
- Vertebral collapse resulting in kyphosis
- Spinal cord compression & deformities
- Neurologic deficits
- Sinus formation
- Paraplegia(Pott's paraplegia) [21].

- Malnourishment
- Low Socioeconomic Status

#### DIAGNOSTIC STUDIES

##### The Mantoux Test (Tuberculin Skin Test)

A standard dose of 5 tuberculin units (TU - 0.1 ml) is injected intradermally. This intradermal injection is termed the **Mantoux technique**. A person who has been exposed to the bacteria is expected to

mount an immune response in the skin containing the bacterial proteins. The reaction is read by measuring the diameter of induration (palpable raised, hardened area) across the forearm (perpendicular to the long axis) in millimetres after 48 to 72 hours later. If there is no induration, the result should be recorded as "0 mm". Erythema (redness) should not be measured. Results are positive in 84-95% of patients with Pott's disease who are not infected with HIV.

### Radiography

Radiography shows lytic destruction of anterior portion of vertebral body, increased anterior wedging, collapse of vertebral body or reactive sclerosis on a progressive lytic process.

### CT scanning

CT scanning provides much better bony detail of irregular lytic lesions, sclerosis, disc collapse, and disruption of bone circumference. Low-contrast resolution provides a better assessment of soft tissue. CT scanning reveals early lesions and is more effective for defining the shape and calcification of soft-tissue abscesses.

### Polymerase Chain Reaction (PCR)

PCR techniques amplify species-specific DNA sequence which is able to rapidly detect and diagnose several strains of mycobacterium without the need for prolonged culture. They have also been used to identify discrete genetic mutations in DNA sequences associated with drug resistance.[10].

### MRI

MRI is the criterion standard for evaluating disc-space infection and osteomyelitis of the spine. This technique is most effective for demonstrating the extension of disease into soft tissues and the spread of tuberculous debris under the ligaments. MRI is also the most effective imaging study for demonstrating neural compression.

The dorsal fluid collection suggests a paravertebral abscess (large arrow) just above the fractured and operated third thoracic vertebra (small arrow). [2,8]

### PREVENTION OF POTT'S DISEASE

Controlling the spread of tuberculosis infection can prevent tuberculous spondylitis and arthritis. Patients who have a positive PPD test may decrease their risk by properly taking medicines to prevent tuberculosis. BCG vaccination is another effective measure to prevent spinal TB. Improvement of socio-economic conditions also helps to prevent this disease. AIDS control

programs should also be initiated as there is chance for co-infection with HIV.

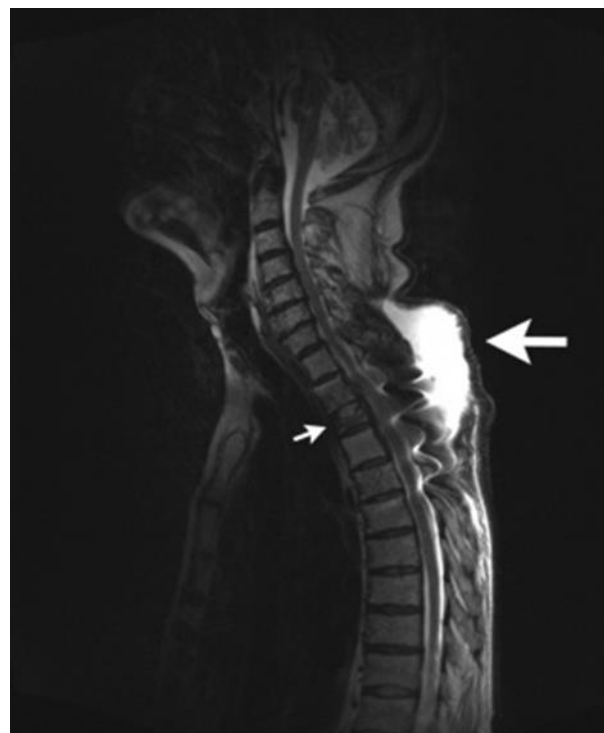

Figure 3: MRI of the thoracic spine (T2-weighted, sagittal reconstruction).

### TREATMENT

Before the advent of effective antituberculosis chemotherapy, Pott's disease was treated with immobilization using prolonged bed rest or a body cast. At that time, the disease carried a mortality rate of 20%, and relapse was common (30%).

The duration of treatment, surgical indications, and inpatient care for Pott's disease have since evolved. Opinions differ regarding whether the treatment of choice should be conservative chemotherapy or a combination of chemotherapy and surgery. The treatment decision should be individualized for each patient, although routine surgery does not seem to be indicated.

#### 1. Non Pharmacological Treatment

- Immobilization using prolonged bed rest or a body cast.
- Chiropractic treatment
- External bracing
- Use of frames, plaster beds, plaster jackets
- Physiotherapy

#### 2. Pharmacological Treatment

According to recommendations issued in 2003 by the US Centers for Disease Control and Prevention (CDC), the Infectious Diseases Society of America, and the American Thoracic Society, a 4-drug

regimen should be used empirically to treat Pott's disease.

Isoniazid and rifampin should be administered during the whole course of therapy. Additional drugs are administered during the first 2 months of therapy. These are generally chosen from among the first-line drugs, which include pyrazinamide, ethambutol, and streptomycin. The use of second-line drugs is indicated in cases of drug resistance.

#### Treatment duration

Studies performed by the British Medical Research Council indicate that tuberculous spondylitis of the thoracolumbar spine should be treated with combination chemotherapy for 6-9 months. However, the research council's studies did not include patients with multiple vertebral involvement, cervical lesions, or major neurologic involvement. Because of these limitations, many experts still recommend chemotherapy for 9-12 months. The duration of therapy should be based on the resolution of active symptoms and the clinical stability of the patient and individualised.

For selected cases with surgical indication that allows complete debridement of the lesion, a combination of surgery and ultra-shortened course of therapy (4.5 months), appears to show comparable outcomes of a combination of surgery and 9 months of drug therapy.

[13,25].

**Isoniazid:** Isoniazid is highly active against *Mycobacterium tuberculosis*. It has good gastrointestinal absorption and penetrates well into all body fluids and cavities.

**Rifampicin:** Rifampicin can be used in combination with at least one other antituberculous drug. It inhibits DNA-dependent bacterial but not mammalian RNA polymerase. Cross-resistance may occur.

**Pyrazinamide:** It is a bactericidal against *Mycobacterium tuberculosis* in an acid environment. It has good absorption from the GI tract and penetrates well into most tissues, including CSF.

**Ethambutol:** Ethambutol has bacteriostatic activity against *M tuberculosis*. It has good GI absorption. CSF concentrations remain low, even in the presence of meningeal inflammation.

**Streptomycin:** It is bactericidal in an alkaline environment. Because it is not absorbed from the GI tract, must be administered parenterally. It exerts action mainly on extracellular tubercle bacilli. It enters the CSF only in the presence of meningeal inflammation. Excretion is almost entirely renal. [9,18,23]

**3.Surgery:** While most patients should respond to medical treatment, a surgical approach needs to be

evaluated and considered. Indications for surgical treatment of Pott disease generally include the following:

- Neurologic deficit - Acute neurologic deterioration, paraparesis, and paraplegia
- Spinal deformity with instability or pain
- No response to medical therapy - Continuing progression of kyphosis or instability
- Large paraspinal abscess
- Nondiagnostic percutaneous needle biopsy sample

The lesion site, extent of vertebral destruction, and presence of cord compression or spinal deformity determine the specific operative approach (kyphosis, paraplegia, tuberculous abscess). Vertebral damage is considered significant if more than 50% of the vertebral body is collapsed or destroyed or a spinal deformity of more than 5° exists. The most conventional approaches include anterior radical focal debridement and posterior stabilization with instrumentation. Newer modalities and techniques are being reported, such as thoracoscopic decompression.

In Pott's disease that involves the cervical spine, the following factors justify early surgical intervention:

- High frequency and severity of neurologic deficits
- Severe abscess compression that may induce dysphagia or asphyxia
- Instability of the cervical spine

#### CONCLUSION

The prognosis for spinal tuberculosis can be improved by early diagnosis and rapid intervention. A high degree of clinical suspicion is required if patients present with chronic back pain, even in the absence of neurological symptoms and signs. Medical treatment is generally effective. Surgical intervention is necessary in advanced cases with marked bony involvement, abscess formation, or paraplegia. Spinal tuberculosis affects young people, so efforts should be made for its effective prevention. Controlling the spread of tuberculosis is only way available to prevent spinal tuberculosis. Patients with Pott's disease should be closely monitored to assess their response to therapy and compliance with medication. Directly observed therapy may be required. The existing first line of treatment is the best available option for treating this disease. The development or progression of neurologic deficits, spinal deformity, or intractable pain should be considered evidence of poor therapeutic response. This raises the possibility of

antimicrobial drug resistance as well as the necessity for surgery. Because of the risk of deformity exacerbations, children with Pott's disease should undergo long-term follow-up until their entire growth potential is completed.

## REFERENCE

1. Jain AK, Dhammi IK. Tuberculosis of the spine: a review. *ClinOrthopRelat Res* 2007;460(July):39–49.
2. Hidalgo JA, Cunha BA. Medscape Reference. Updated 2011 Dec 5. Accessed 2012 Mar 28.
3. Cherian A, Thomas SV. Central nervous system tuberculosis. *Afr Health Sci*. 2011 (1): 116-127.
4. Benzagmout M, Boujraf S, Chakour K, Chaoui M. Pott's disease in children. *Surgical Neurology International*.2011; 2(1).1-5.
5. Nagashima H, Yamane K, Nishi T, Nanjo Y, Teshima R. Recent trends in spinal infections: retrospective analysis of patients treated during the past 50 years. *International Orthopaedics*. 2010; 34(3): 395-399.
6. Schirmer P, Renault CA, Holodniy M. Is spinal tuberculosis contagious? *International Journal of Infectious Diseases*. Aug 2010; 14(8): 649-666.
7. Kumar R, Srivastava K, Tiwari RK. Surgical management of Pott's disease of the spine in pediatric patients: A single surgeon's experience of 8 years in a tertiary care center. *Journal of Pediatric Neurosciences*.2011; 6: 101-108.
8. Khoo LT, Mikawa K, Fessler RG. A surgical revisit of Pott distemper of the spine. *The Spine Journal*.2003; 130-145.
9. Ramachandran S, Clifton IJ, Collyns TA, et al. The treatment of spinal tuberculosis: a retrospective study. *Int J Tuberc Lung Dis*. 2005;9:541–44.
10. Jain AK. Tuberculosis of the spine: a fresh look at an old disease. *J Bone Joint Surg Br* 2010; 92(7):905–13
11. Turgut M. Spinal tuberculosis (Pott's disease): Its clinical presentation, surgical management, and outcome. A survey study on 694 patients. *Neurosurg Rev*. 2001; 24:8–13.
12. Goodman CC, Snyder TES. *Differential Diagnosis for Physical Therapists: Screening for Referral*. 4th ed. St. Louis, MO: Saunders Elsevier; 2007:345
13. Kaila R, Malhi AM, Mahmood B, Saifuddin A. The incidence of multiple level noncontiguous vertebral tuberculosis detected using whole spine MRI. *J Spinal Disord Tech*. 2007;20:78–81.
14. Colmenero JD, Jiménez-Mejías ME, Reguera JM, et al. Tuberculous vertebral osteomyelitis in the new millennium: Still a diagnostic and therapeutic challenge. *Eur J ClinMicrobiol Infect Dis*. 2004; 23:477–83.
15. Weng CY, Chi CY, Shih PJ, et al. Spinal tuberculosis in non-HIV-infected patients: 10 year experience of a medical center in central Taiwan. *J MicrobiolImmunolInfect*. 2010;43:464–69.
16. Johansen IS, Nielsen SL, Hove M, et al. Characteristics and clinical outcome of bone and joint tuberculosis from 1994 to 2011: A retrospective register-based study in Denmark. *Clin Infect Dis*. 2015;61:554–62.
17. Moorthy S, Prabhu NK. Spectrum of MR imaging findings in spinal tuberculosis. *Am J Roentgenol*2002;179(4):979–83
18. Ramachandran S, Clifton IJ, Collyns TA, et al. The treatment of spinal tuberculosis: a retrospective study. *Int J Tuberc Lung Dis*. 2005;9:541–44.
19. Dass B, Puet TA, Watanakunakorn C. Tuberculosis of the spine (Pott's disease) presenting as 'compression fractures'. *Spinal Cord* 2002;40(11):604–8
20. World Health Organization. Stop TB Dept .4th edition. Geneva: World Health Organization; 2010. Treatment of tuberculosis: guidelines.
21. Tuli SM. Treatment of neurological complications in tuberculosis of spine. *J Bone Joint Surg Am*1969;51(4):680–92.
22. Khoo LT, Mikawa K, Fessler RG. A surgical revisit of Pott distemper of the spine. *The Spine Journal*.2003; 130-145.
23. Rezai AR, Lee M, Cooper PR, et al. Modern management of spinal tuberculosis. *Neurosurgery*. 1995;36:87–97.
24. Alavi SM, Sharifi M. Tuberculous spondylitis: risk factors and clinical/paraclinical aspects in the south west of Iran. *J Infect Public Health* 2010;3(4):196–200.
25. Okada Y, Miyamoto H, Uno K, Sumi M. Clinical and radiological outcome of surgery for pyogenic and tuberculous spondylitis: Comparisons of surgical techniques and disease types. *J Neurosurg Spine*. 2009;11(5):620–27.
26. Statens serum institute Tuberculosis 2013. *Epi-News*. 2015. p. 3.

27. Krogh K, Surén P, Mengshoel AT, Brandtzæg P. Tuberculosis among children in Oslo, Norway, from 1998 to 2009. *Scand J Infect Dis.* 2010;42:866–72.
28. Herath S, Lewis C. Pulmonary involvement in patients presenting with extra-pulmonary tuberculosis: Thinking beyond a normal chest x-ray. *J Prim Health Care.* 2014;6:64–68.
29. Cheng VC, Yam WC, Hung IF, et al. Clinical evaluation of the polymerase chain reaction for the rapid diagnosis of tuberculosis. *J ClinPathol.* 2004;57:281–85.
30. Bakhsh A. Medical management of spinal tuberculosis: An experience from Pakistan. *Spine.* 2010;35:787–91.
31. Park DW, Sohn JW, Kim EH, et al. Outcome and management of spinal tuberculosis according to the severity of disease: A retrospective study of 137 adult patients at Korean teaching hospitals. *Spine.* 2007;32:130–35.
32. Gautam MP, Karki P, Rijal S, Singh R. Pott's spine and Pott's paraplegia. *J Nep Med Assoc* 2005;44(159):106–15.
33. Berk RH, Yazici M, Atabey N, Ozdamar OS, Pabuccuoglu U, Alici E. Detection of Mycobacterium tuberculosis in formaldehyde solution-fixed, paraffin-embedded tissue by polymerase chain reaction in Pott's disease. *Spine (Phila Pa 1976)* 1996;21(17):1991–5.
34. World Health Organization. Treatment of tuberculosis: guidelines. 4th ed. (WHO/HTM/TB/2009.420) World Health Organization; 2010 [assessed on 2011 Apr 16].