



## Possible role of bee pollen dietary supplement in remediation of hepato- and geno-toxic effects of aflatoxins in rats

Nermeen Borai El-Borai<sup>1\*</sup>, Badr El-Said El-Bialy<sup>1</sup>, Amira Shehata Abd El Latif<sup>2</sup>, Mostafa Abd El-Gaber Mohamed<sup>3</sup>, Amanallah Ahmed El-Bahrawy<sup>4</sup>

<sup>1</sup>Department of Forensic Medicine and Toxicology, Faculty of Veterinary Medicine, University of Sadat City, Sadat City, Egypt.

<sup>2</sup>Department of Pharmacology, Faculty of Veterinary Medicine, Kafr El Sheikh University, Egypt.

<sup>3</sup>Department of Veterinary Pathology, Faculty of Veterinary Medicine, Minufya University, Shebin Elkome, Egypt.

<sup>4</sup>Department of Veterinary Pathology, Faculty of Veterinary Medicine, University of Sadat City, Sadat City, Egypt.

*Received: 12-01-2018 / Revised Accepted: 25-02-2018 / Published: 11-03-2018*

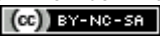
### ABSTRACT

**Background:** Mycotoxins are toxic secondary fungal metabolites that implicated in many adverse health effects and economic losses. Recently, bee pollen (BP) has attracted attention as a useful preventive and therapeutic agent referring to its antioxidant properties. **Objective:** This study aimed to evaluate the potential modulatory effect of BP against aflatoxins (AFs)- induced hepato- and geno- toxicity in rats. **Methodology:** Twenty four albino rats were randomly divided into four equal groups and treated for 30 days. Control group (fed basal diet); AFs group (3 mg/kg basal diet); BP group (20 g/kg basal diet) and AFs+BP group. **Results:** AFs in diet induced elevation in serum ALT and AST activities and TC, TG, LDL and VLDL levels with reduction in HDL level. This was associated with increase in hepatic H<sub>2</sub>O<sub>2</sub> with decrease in GSH and NO levels. Furthermore, AFs-induced DNA damage of hepatocytes. Additionally, degeneration, necrosis, and mononuclear cells infiltration were observed in liver of AFs- intoxicated rats. BP supplementation induced a remarkable amelioration of these toxic effects, suggesting its protective antioxidant properties. **Conclusion:** BP could be used as a biomedical supplement in diet to protect animals and humans from hepato- and geno-toxic effects of AFs.

**Keywords:** Aflatoxins (AF), bee pollen (BP), hepatotoxicity, DNA, genotoxicity.

**Address for Correspondence:** Nermeen Borai El Borai, PhD, Department of Forensic Medicine and Toxicology, Faculty of Veterinary Medicine, University of Sadat City, Sadat City, 32897, Egypt.  
E-mail: nermeenborai@yahoo.com

**How to Cite this Article:** Nermeen Borai El-Borai, Badr El-Said El-Bialy, Amira Shehata Abd El Latif, Mostafa Abd El-Gaber Mohamed, Amanallah Ahmed El-Bahrawy. Possible role of bee pollen dietary supplement in remediation of hepato- and geno-toxic effects of aflatoxins in rats World J Pharm Sci 2018; 6(3): 91-97.

This is an open access article distributed under the terms of the Creative Commons Attribution-Non Commercial-Share Alike 4.0 International License, which allows adapt, share and build upon the work non-commercially, as long as the author is credited and the new creations are licensed under the identical terms. 

## INTRODUCTION

Mycotoxicosis is a disease caused by ingestion of contaminated foods or feeds with mycotoxins which are toxic secondary fungal metabolites that induce adverse toxic effects to the exposed animals or human [1-3]. Aflatoxins (AFs), the most common mycotoxins, are a family of extremely toxic mutagenic and carcinogenic compounds produced by a large number of *Aspergillus* species mainly *A. flavus*, and *A. parasiticus* [2].

Aflatoxins usually target the liver and exert immunosuppressive, hepatotoxic, genotoxic and carcinogenic effects to exposed human and animals [2-5]. The generation of reactive oxygen species (ROS) and lipid peroxidation (LPO) is the suggested major mechanism in toxicity of AFs [4]. The mutagenic effect of AFs has been well documented in previous *in vitro* and *in vivo* studies. DNA adducts and breaks, gene mutations and inhibition of DNA repair have been determined, as well as increases in the rate of chromosomal aberrations, micronuclei, and sister chromatid exchanges (SCE) [6]. There is an urgent need to new strategies to control mycotoxicosis other than the current chemical anti-mycotoxins that have a lot of adverse effects. Natural products always found to be reliable and safe sources for several ailments. Among them bee pollen is a good and new area of research.

Bee pollen (BP) is apicultural honeybee product composed of nutritionally valuable substances [7] and has been applied for centuries in alternative medicine as well as in food diets and supplementary nutrition for human and animals due to its nutritional and physiological properties [8]. It is well documented that bee pollens, prepared by bee by collecting pollens from plants, are rich in essential amino acids, protein, unsaturated fatty acids and also contains many vitamins, minerals and trace elements which contribute to the health effects [9]. In addition, pollen contains significant amounts of polyphenolic substances, mainly flavonoids [10].

Pollen and pollen products are important traditional herbal medicine widely used in the treatment of various diseases as it has many pharmacological functions as it has antimicrobial and anti-inflammatory effects [11,12]. Furthermore, previous studies proved the antioxidative, hepatoprotective, nephroprotective and hypolipidemic [4, 13-15] properties of BP.

Taking into consideration the above mentioned information about the therapeutic effect of BP, our study aimed to evaluate if bee pollen

supplementation could alleviate hepato- and genotoxic effects on rat fed diet containing aflatoxins.

## MATERIALS AND METHODS

**Animals:** A total of 24 adult male Wistar albino rats (120–150 g) were purchased from AL Zyade Experimental Animals Production Center, Giza, Egypt. All animals were kept under hygienic condition in polypropylene cages with mesh wire tops and in well ventilated laboratory room (22-25°C, 60-65% relative humidity, natural daily dark/light cycle). Free access to balanced diet and tap water was allowed for 2 weeks prior to the start of experiments for acclimatization. The animal rearing and experimental design were ethically approved by the International Animal Care and Use Committee IACUC, Faculty of Veterinary Medicine, University of Sadat City, Egypt.

**Aflatoxins Production:** Toxigenic *Aspergillus flavus* isolated from broiler feed was obtained from the Mycology Department of the Animal Health Research Institute, Giza, Egypt and confirmed by sub-culture onto Malt Extract and Czapek Dox agar and incubation for 8 day at 25°C. The *A. flavus* was screened for aflatoxins (AFs) production using Thin Layer Chromatography (TLC). Presence of various AFs was qualitatively confirmed by the appearance of blue fluorescence on the plate and comparison of the spot's Retention Factor (RF) value versus the RF of a known standard.

Crushed yellow corn, obtained commercially from Al-Ahram Company poultry rations (Giza, Egypt) was verified as completely free from fungal or mycotoxins contaminations by gross and TLC examination. The corn was placed in flasks and then autoclaved at 121 °C for 15 min on three successive days. The corn was then treated with 10 ml spore suspension (at 10<sup>7</sup> spores/ml) and the whole mixture fermented by incubation at 28-30°C for 21 days. After incubation, the flask was dried in a 60°C oven for 24 h to kill the fungus and then grinding the sample with grinder. A representative 25 grams of sample of the upper growth culture were extracted for AFs determination according to the Official Methods Program (AOAC) by TLC methods [16]. It was found that the corn cultured with fungus contain 150 mg/kg of total AFs. The corn was incorporated into the basal diet to provide the desired level of 3mg of total AFs/kg diet.

**Bee pollen (BP)** was purchased from apiary in Sadat City, Egypt.

**Diagnostic kits:** Kits for assaying serum alanine aminotransferase (ALT), aspartate aminotransferase (AST), total cholesterol (TC),

triglycerides (TG) and HDL; and hydrogen peroxide (H<sub>2</sub>O<sub>2</sub>), nitric oxide (NO) and reduced glutathione (GSH) in liver tissue homogenate were purchased from the Biodiagnostic Company, Dokki, Giza, Egypt. All the other chemicals and reagents were of analytical grades and purchased from Sigma and Acmatic Companies, Egypt.

**Treatment Schedule:** The rats were randomly divided into four equal groups, each of 6 rats. **Control group** fed with free basal diet. **AFs group:** fed with basal diet containing AFs 3mg/kg [17] for 30 days. **BP group:** fed with basal diet containing 20g/kg (2%) BP [18]. **AFs + BP group:** fed with basal diet containing both AFs and BP.

**Collection and Preparation of Samples:** At the end of the experiment, all rats were fasted overnight, anaesthetized, blood samples were collected from median canthus of the eye and centrifuged at 3000 rpm for 15 minutes, and then serum was kept at -20°C for further biochemical analysis. After blood collection, rats were euthanized by cervical dislocation for livers excision. Specimens of liver of each rat were collected and stored at -20°C for tissue biochemical investigations. Other Parts were kept in phosphate buffer saline (PBS) at -20 °C for Comet assay. Additional parts were kept in 10% neutral buffer formalin for histopathological examination.

**Serum Biochemical Analysis:** Serum activities of ALT and AST were calorimetrically estimated according to **Reitman and Frankel [19]**. The levels of TC, TG and HDL-C were estimated calorimetrically according to **Allain et al. [20]**, **Fassati and Principe [21]** and **Lopez-Virella et al. [22]**, respectively.

Serum LDL-C and VLDL-C levels were calculated according to the equations of **Lee and Nieman [23]** as follows:

$$\text{LDL (mg/dl)} = \text{TC} - \text{HDL} - \text{TG}/5$$

$$\text{VLDL (mg/dl)} = \text{TG}/5$$

**Hepatic oxidant/antioxidant biomarkers:** The concentrations of hydrogen peroxide (H<sub>2</sub>O<sub>2</sub>), reduced glutathione (GSH) and nitric oxide (NO) in liver tissue homogenates were estimated according to **Montgomery and Dymock [24]**, **Fossati et al. [25]** and **Beutler et al. [26]**, respectively.

**Comet Assay:** DNA damage of hepatocytes was determined according to **Frei et al. [27]**. Out of 100 randomly selected nuclei were photographed and scanned, for detection of tail length, DNA% in the tail and the tail moment. DNA damage in the cells was estimated by measuring the degree of fluorescence or intensity of DNA migration in tail and tail length. The tail moment was calculated as tail length multiplied by percentage of migrated DNA divided by 100.

**Histopathological Examination:** After fixation of liver tissue in 10% neutral buffered formalin for 2 days, tissues were trimmed (3 mm thickness) and washed under running water over night. The samples were then dehydrated using ascending grades of ethyl alcohol and cleared in xylol for 2-4 hours to remove the alcohol. The prepared tissue specimens were then embedded in paraffin wax to form blocks and then sectioned by Leica microtome into thin sections of 5 µm thickness. The tissue sections were put onto glass slides deparaffinized and lastly stained by H&E stain and examined by light microscope [28].

**Statistical Analysis:** Values are presented as mean ± standard error of mean (SEM). All statistical analyses were performed using SPSS (Statistical package for Social Sciences) Version 16 released on 2007, the significance between groups was calculated using one-way analysis of variance (ANOVA) followed by Tukey's Test for post hoc analysis at  $P \leq 0.05$ .

## RESULTS

**Effects on Serum Biochemical Parameters:** The toxic effect of AFs and the protective effect of BP on serum biochemical parameters were summarized in Table 1. In comparing with control group, AFs in diet at a level of 3 mg/kg significantly increased serum ALT and AST activities; TC, TG, LDL and VLDL levels. While, AFs- induced significant reduction in serum HDL level at  $P \leq 0.05$ . However, rats fed on diet containing AFs and BP significantly improved all the altered parameters compared to those of AFs group. No significant changes were recorded in BP group compared to control group.

**Table 1: Mean values of serum biochemical parameters in the different groups.**

Parameters/ Group	Control	AFs	BP	AFs + BP
ALT (U/ml)	44.80 ± 2.03 <sup>a</sup>	66.20 ± 3.12 <sup>b</sup>	43.20 ± 2.47 <sup>a</sup>	47.20 ± 2.45 <sup>a</sup>
AST (U/ml)	85.25 ± 3.40 <sup>a</sup>	107.5 ± 2.78 <sup>b</sup>	77.25 ± 2.75 <sup>a</sup>	79.25 ± 2.32 <sup>a</sup>
TC (mg/dl)	170.4 ± 3.17 <sup>a</sup>	205.2 ± 4.85 <sup>b</sup>	165.6 ± 3.69 <sup>a</sup>	175.2 ± 2.85 <sup>a</sup>
TG (mg/dl)	133.2 ± 1.46 <sup>ab</sup>	146.8 ± 2.59 <sup>c</sup>	127.4 ± 1.6 <sup>a</sup>	136.4 ± 1.21 <sup>b</sup>
HDL (mg/dl)	81.6 ± 2.22 <sup>b</sup>	61.8 ± 1.85 <sup>a</sup>	79.6 ± 2.04 <sup>b</sup>	68.8 ± 1.85 <sup>a</sup>
LDL (mg/dl)	62.08 ± 2.11 <sup>a</sup>	114.04 ± 3.56 <sup>c</sup>	60.52 ± 3.96 <sup>a</sup>	79.12 ± 3.65 <sup>b</sup>
VLDL (mg/dl)	26.64 ± 0.29 <sup>ab</sup>	29.36 ± 0.52 <sup>c</sup>	25.48 ± 0.32 <sup>a</sup>	27.28 ± 0.24 <sup>b</sup>

Values are presented as mean ±SE. n=6

Different superscripts in the same row are significantly different at (P ≤0.05).

**Effects on hepatic oxidant/ antioxidant markers:**

The changes in hepatic oxidant/ antioxidant levels were summarized in Table 2. In comparison with control group, AFs significantly increased hepatic H<sub>2</sub>O<sub>2</sub> and decreased GSH levels at P≤0.05. However, rats exposed to AFs+BP showed

improvement and to some extent returned H<sub>2</sub>O<sub>2</sub> and GSH values to that of control group. There were no significant changes in hepatic NO levels among different groups. No significant changes in hepatic H<sub>2</sub>O<sub>2</sub>, GSH and NO levels were recorded in BP group compared to control group.

**Table 2: Mean values of hepatic oxidant/antioxidant markers in the different groups.**

Parameters/ Group	Control	AFs	BP	AFs + BP
H <sub>2</sub> O <sub>2</sub> (mM/g tissue)	1.47±0.03 <sup>a</sup>	1.75±0.02 <sup>b</sup>	1.45±0.03 <sup>a</sup>	1.57±0.02 <sup>a</sup>
GSH (mg/g tissue)	112.76 ±1.21 <sup>b</sup>	84.19±2.24 <sup>a</sup>	111.2±1.88 <sup>b</sup>	108.4±3.39 <sup>b</sup>
NO (µmol/g tissue)	47.12±2.72	44.05±1.71	44.49±1.28	46.1±1.3

Values are presented as mean ±SE. n=6

Different superscripts in the same row are significantly different at (P ≤0.05).

**Effects on DNA:** Comet assay results were summarized in Table 3 and Figure 1. Compared to control group, AFs genotoxicity was confirmed by significant increase in DNA damage%, tail length, tail DNA%, and tail moment while BP group had

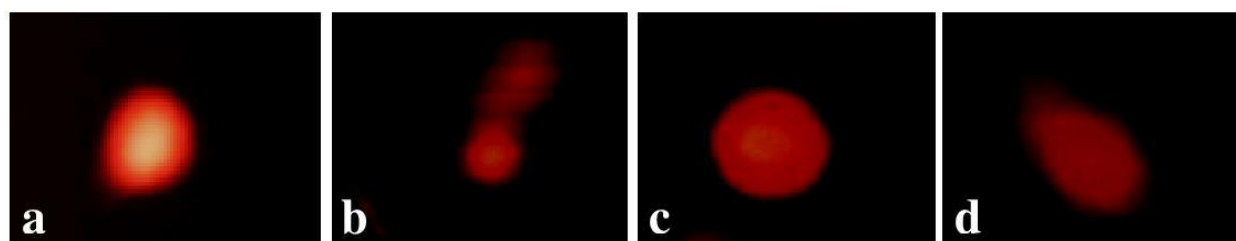
no significant changes than those of control. AFs+BP- exposed rats approved the genoprotective effect of BP by decreasing the damaged DNA%, tail length, tail DNA% and tail moment than that of aflatoxicated rats.

**Table 3: Mean values of comet assay parameters of hepatocytes in the different groups.**

Parameters/ Group	Control	AFs	BP	AFs + BP
Damaged DNA%	21.0±1.52 <sup>a</sup>	31.3±1.45 <sup>b</sup>	16.6±1.66 <sup>a</sup>	20.3±1.45 <sup>a</sup>
Tail length (µm)	14.47±1.2 <sup>a</sup>	21.03±0.48 <sup>b</sup>	13.3±1.4 <sup>a</sup>	17.8±1.6 <sup>ab</sup>
Tail DNA%	1.62±0.07 <sup>a</sup>	2.23±0.12 <sup>b</sup>	1.50±0.05 <sup>a</sup>	1.83±0.03 <sup>a</sup>
Tail moment	0.24±0.02 <sup>ab</sup>	0.47±0.03 <sup>c</sup>	0.20±0.03 <sup>a</sup>	0.33±0.02 <sup>b</sup>

Values are presented as mean ±SE. n=6

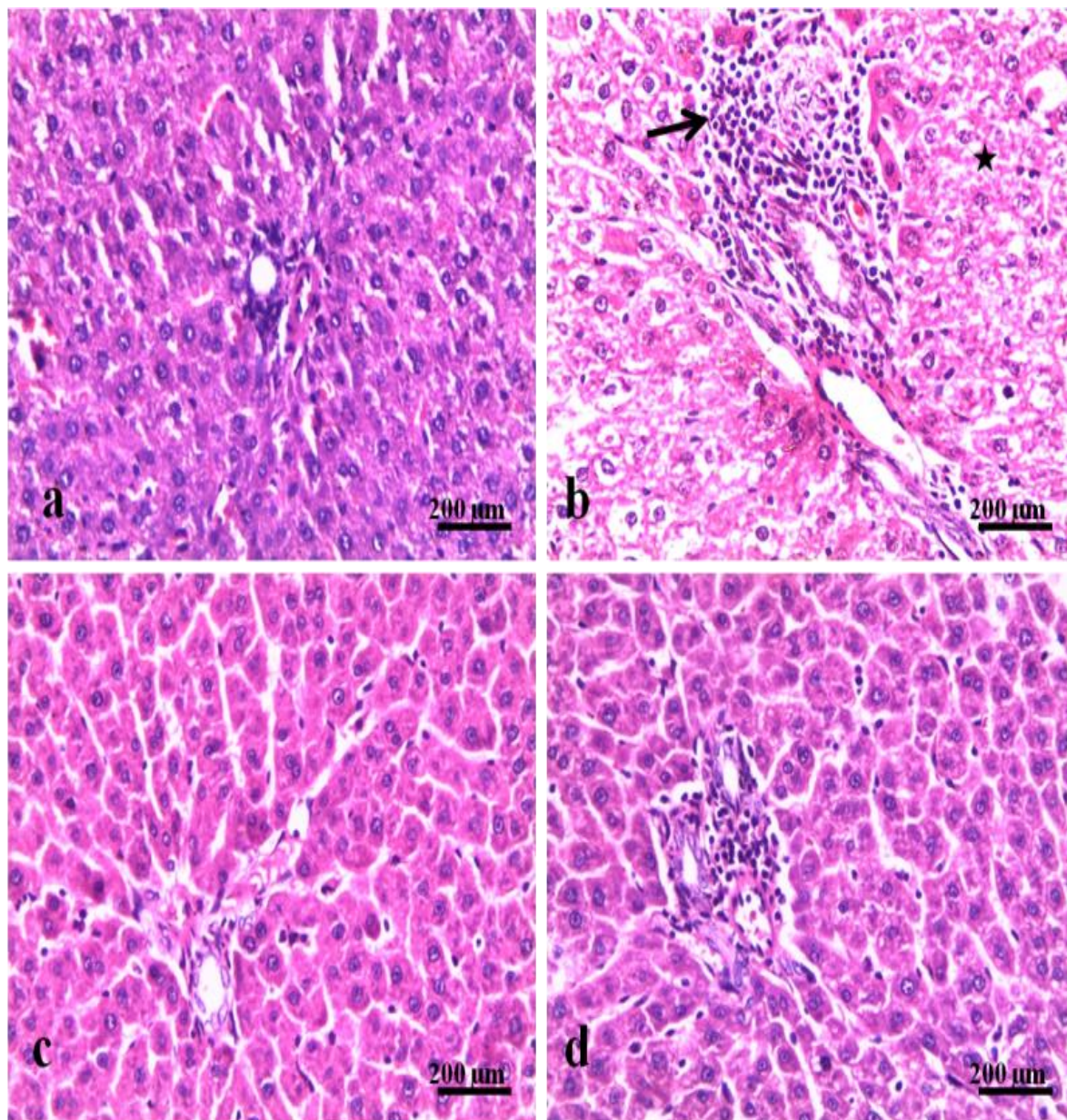
Different superscripts in the same row are significantly different at (P ≤0.05).



**Fig. 1.** Comet assay of hepatocytes. **a:** Control group, **b:** AFs group, **c:** BP group, and **d:** AFs+ BP group

**Effects on hepatic histoarchitecture:** Normal hepatic histological structure was observed in control (Fig. 2a) and BP (Fig.2c) groups. Liver of AFs- exposed rats showed vacoulation, degeneration and necrosis in hepatocytes. These

were with multifocal mononuclear cells infiltration (Fig.2b). Rats of AFs+BP group showed improvement in the hepatic histoarchitecture except from few mononuclear cells infiltration (Fig.2d).



**Fig.2.** Liver photomicrographs of: (a) control group showed normal hepatic parenchyma. (b) AFs group showed vacoulation (star), degeneration and necrosis, and mononuclear cells infiltration (arrow) in the hepatic parenchyma.(c) BP group showed normal hepatic parenchyma. (d) AFs+BP group showed few cell infiltrations (H&E, X20).

## DISCUSSION

Aflatoxins, a group of mycotoxins, are one of the most important biological pollutants that are extremely toxic to animals and humans [2,3]. Bee pollen is a product with added value because of its certain health benefits such as an antioxidant, anti-inflammatory and antimicrobial properties [4,11,12].

In the current study, AFs significantly increased serum ALT and AST activities which are sensitive markers for hepatic necrosis, suggesting degenerative changes and disturbance of liver functions as proposed by others [3,29] that commonly associated with hyperlipidemia and decrease in HDL level [29-31], indicating the impairment of liver function, particularly on lipid metabolism.

In the current study, AFs increased hepatic concentration of H<sub>2</sub>O<sub>2</sub> that could be attributed firstly to the generation of ROS such as H<sub>2</sub>O<sub>2</sub>, hydroxyl and superoxide radicals through the oxidation of AFs to its reactive intermediate (8,9 epoxide) by hepatic cytochrome P450 [32]. Secondly, AFs decreased GSH in this study and previous studies [33,34]. The decrease of GSH is due to its conjugation with aflatoxin epoxide [35].

GSH is essential for scavenging and conjugating of free radicals and H<sub>2</sub>O<sub>2</sub> generated by toxic chemicals [32]. Aflatoxins in this study reduced hepatic NO level that may referred to its suppressive effect on macrophage functions. Previously, it was suggested that AFB<sub>1</sub> reduces NO production from murine peritoneal macrophages which is mediated by the reduction of inducible nitric oxide synthase (iNOS) activity [36].

Previous studies have shown that increased ROS can cause oxidative damage to chromosomes and DNA, contributing to cytotoxicity and genotoxicity of AFs [37-39]. The Comet assay confirmed the genotoxicity of AFs through increasing DNA damage and percentage of DNA in tail as previously reported [5].

The serum and tissue biochemical changes as well as DNA damage recorded in AFs- exposed rats are compatible with the observed hepatic histological alterations recorded in this study and previous studies [29-31].

Rats exposed to AFs+BP showed improvements in the altered serum and tissue biochemical parameters concurrently with decreasing percentage of damaged DNA and the hepatic histopathological alterations that could be

attributed to the hypolipidemic, hepatoprotective effect of BP as previously reported [13-15] that may be due to its high phenolic and flavonoid contents [12], indicating its antioxidant effect. Regarding to the effect of BP, there were no changes in the estimated parameters compared to those of control rats except decrease of NO production due to its potent anti-inflammatory activity that referred to its phenolic and flavonoid contents [11,40].

## CONCLUSION

Based on our present observations, we proved the protective role of bee pollen against aflatoxins-induced hepato- and geno-toxicity. Therefore, addition of bee pollen to the diet may provide economical and public health benefits.

## ACKNOWLEDGMENTS

The authors thank Prof. Dr. Eman Mahmoud El-Diasty (Department of Mycology, Animal Health Research Institute, Dokki, Egypt) for her efforts in the preparation of aflatoxins.

## CONFLICTS OF INTEREST

The authors declare no conflicts of interest. The authors alone are responsible for the content of this manuscript.

## REFERENCES

1. Jard G et al. A Review of mycotoxin reduction in food and feed: from prevention in the field to detoxification by adsorption or transformation. Food Addit Contam Part A Chem Anal Control Expo Risk Assess 2011; 28:1590-1609.
2. Zain ME. Impact of mycotoxins on humans and animals. J Saudi Chem Soc 2011; 15:129-144.
3. Sun LH et al. Hepatotoxic effects of mycotoxin combinations in mice. Food Chem Toxicol 2014; 74: 289-293.
4. El-Bialy BE et al. Experimental Studies on Some Immunotoxicological Aspects of Aflatoxins Containing Diet and Protective Effect of Bee Pollen Dietary Supplement. Pak J Biolog Sci 2016; 19: 26-35.
5. Corcuera L et al. Genotoxicity of Aflatoxin B<sub>1</sub> and Ochratoxin A after simultaneous application of the in vivo micronucleus and comet assay. Food Chem Toxicol 2015; 76: 116-124.
6. Madrigal-Santillán E et al. Investigation on the Protective Effect of  $\alpha$ -Mannan against the DNA Damage Induced by Aflatoxin B<sub>1</sub> in Mouse Hepatocytes. Int J MolSci 2009; 10: 395-406.
7. Saric A et al. Antioxidant effects of flavonoid from Croatian *Cystusincanus* L. rich bee pollen. Food Chem Toxicol 2009; 47:547-554.
8. da Silva GR et al. Identification of sugar, amino acids and minerals from the Pollen of jandaíra stingless bees (*Meliponasubnitida*). Food and NutreSci 2014; 5: 1015-1021.

9. Campos MGR et al. Pollen composition and standardisation of analytical methods. *J Apicult Res* 2008; 47: 154–161.
10. de Arruda VAS et al. Dried bee pollen: B complex vitamins, physicochemical and botanical composition, *J Food Compos Anal* 2013; 29: 100-105.
11. Maruyama H et al. Antiinflammatory effect of bee pollen ethanol extract from *Cistus* sp. of Spanish on carrageenan-induced rat hind paw edema. *BMC Complem Altern Med* 2010; 10: 1-11.
12. Komosinska-Vassev K et al. Bee pollen: Chemical composition and therapeutic application. *Evid Based Complem Altern Med* 2015; 297425- 31.
13. Eraslan G et al. Evaluation of protective effect of bee pollen against propoxur toxicity in rat. *Ecotoxicol Environ Saf* 2009a; 72: 931–937.
14. Eraslan G et al. Effect of carbaryl on some biochemical changes in rats: the ameliorative effect of bee pollen. *Food Chem Toxicol* 2009b; 47:86–91.
15. Yıldız O et al. Hepatoprotective Potential of Chestnut Bee Pollen on Carbon Tetrachloride-Induced Hepatic Damages in Rats. *Evid Based Complem Altern Med* 2013; 461478-87.
16. AOAC. Natural Poisons, in: Horwitz, W. (Ed), Official methods of analysis of the association of official analytical chemists, thirteenth ed. Washington, D.C., pp 1980.414–433.
17. Abdel-Wahhab MA et al. *Zizyphus spina-christi* extract protects against aflatoxin B1-initiated hepatic carcinogenicity. *Afr J Tradit Complem Altern Med* 2007; 4: 248-256.
18. Khalil FA, Elsheikh NM. The Effects of Dietary Egyptian Propolis and Bee Pollen Supplementation against Toxicity of Sodium Fluoride in Rats. *J Amer. Sci* 2010; 6: 310-316.
19. Reitman S, Frankel S. Colorimetric determination of serum oxalacetic and glutamic pyruvic transaminase. *Amer. J. Clin. Pathol.* 1957; 28: 56-63.
20. Allain C et al. Enzymatic determination of total serum cholesterol. *Clin.Chem.* 1974; 20: 470–475.
21. Fassati P, Principe L. Serum triglycerides determined colorimetrically with an enzyme that produces hydrogen peroxide. *Clin. Chem.* 1982; 28: 2077-2080.
22. Lopez-Virella MF et al. Cholesterol determination in high density lipoproteins separated by three different methods. *Clin Chem.* 1977; 23: 882–884.
23. Lee R, Nieman D. *Nutrition Assessment*. 2nd Ed., Mosby Co., Missouri, USA. 1996.
24. Aebi H. Catalase in vitro. *Methods Enzymol* 1984; 105: 121–26.
25. Montgomery HAC and Dymock JF. The determination of nitrite in water. *Analyst* 1961; 86: 414-416
26. Beutler EK et al. Improved method for the determination of blood glutathione. *J Lab Clin Med* 1963; 61: 882-888.
27. Frei E et al. N-nitroso-dimethylamine is activated in microsomes from hepatocytes to reactive metabolites which damage DNA of non-parenchymal cells in rat liver. *Toxicol Lett* 2001; 123: 227–234.
28. Bancroft D et al. *Theory and practice of histological techniques*. 4<sup>th</sup> edition, Churchill Livingstone, Edinburgh, London, Melbourne, 1996.
29. El-Nekeety AA et al. Quercetin inhibits the cytotoxicity and oxidative stress in liver of rats fed aflatoxin-contaminated diet. *Toxicol Rep* 2014; 1: 319–329.
30. Gholami-Ahangaran M et al. Evaluation of turmeric (*Curcuma longa*) effect on biochemical and pathological parameters of liver and kidney in chicken aflatoxicosis. *Pharm Biol* 2016; 54: 780-787.
31. Shi D et al. Protective effects of selenium on aflatoxinB1-induced mitochondrial permeability transition, DNA damage, and histological alterations in duckling liver. *Biol. Trace Elem Res* 2015; 163: 162–168.
32. Abdel-Aziem SH et al. Ameliorative effects of thyme and calendula extracts alone or in combination against aflatoxins-induced oxidative stress and genotoxicity in rat liver. *Cytotechnology* 2014; 66: 457–470.
33. Abdulmajeed NA. Therapeutic ability of some plant extracts on aflatoxin B1 induced renal and cardiac damage. *Arab J Chem* 2011; 4: 1–10.
34. Rotimi S et al. Effects of Ginger Juice Aflatoxin-Induced Oxidative Stress in Rats. *The FASEB Journal* 2015; 29: Supplement 621.5.
35. Bernabucci U et al. Aflatoxin B1 and fumonisin B1 affect the oxidative status of bovine peripheral blood mononuclear cells. *Toxicol In Vitro* 2011; 25: 684–691.
36. Chatterjee D, Ghosh P. Sub-cytotoxic concentration of AflatoxinB2 prevents NO-mediated increased mitochondrial membrane potential and intracellular killing of *Candida albicans* in macrophages. *Adv Life Sci* 2012; 2: 52-56.
37. Golli-Bennour EE et al. Cytotoxicity and genotoxicity induced by aflatoxin B1, ochratoxin A, and their combination in cultured Vero cells. *Biochem Mol Toxicol* 2010; 24: 42-50.
38. Brahma D et al. Chemopreventive effect of cactus *Opuntia ficus indica* on oxidative stress and genotoxicity of aflatoxin B1. *Nutr Metab (Lond)* 2011; 8: 73.
39. Mary VS et al. Reactive oxygen species sources and biomolecular oxidative damage induced by aflatoxin B1 and fumonisin B1 in rat spleen mononuclear cells. *Toxicology* 2012; 302: 299–307.
40. Akkol EK et al. In vivo activity assessment of a “honey-bee pollen mix” formulation. *Pharm Biol* 2010; 48: 253-259.